

# The Potential of Aqueous Humor Sampling in Diagnosis, Prognosis, and Treatment of Retinoblastoma

Anbukkarasi Muniyandi,<sup>1,2</sup> Nathan R. Jensen,<sup>2,5</sup> Nirupama Devanathan,<sup>2</sup> Helen Dimaras,<sup>6-9</sup> and Timothy W. Corson<sup>1-4,10</sup>

<sup>1</sup>Department of Pharmacology & Toxicology, Indiana University School of Medicine, Indianapolis, Indiana, United States

<sup>2</sup>Eugene and Marilyn Glick Eye Institute, Department of Ophthalmology, Indiana University School of Medicine, Indianapolis, Indiana, United States

<sup>3</sup>Department of Biochemistry and Molecular Biology, Indiana University School of Medicine, Indianapolis, Indiana, United States

<sup>4</sup>Indiana University Melvin and Bren Simon Comprehensive Cancer Center, Indianapolis, Indiana, United States

<sup>5</sup>Department of Ophthalmology, University of Utah, Salt Lake City, Utah, United States

<sup>6</sup>Department of Ophthalmology and Vision Sciences, Hospital for Sick Children, Toronto, Ontario, Canada

<sup>7</sup>Child Health Evaluative Sciences Program, Hospital for Sick Children, Toronto, Ontario, Canada

<sup>8</sup>Department of Ophthalmology and Vision Sciences, University of Toronto, Toronto, Ontario

<sup>9</sup>Division of Clinical Public Health, University of Toronto, Toronto, Ontario, Canada

<sup>10</sup>Leslie Dan Faculty of Pharmacy, University of Toronto, Toronto, Ontario, Canada

Correspondence: Timothy W. Corson, Leslie Dan Faculty of Pharmacy, University of Toronto, 144 College Street, Toronto, ON M5S 3M2, Canada; [tim.corson@utoronto.ca](mailto:tim.corson@utoronto.ca).

**Received:** June 24, 2023

**Accepted:** November 27, 2023

**Published:** January 5, 2024

Citation: Muniyandi A, Jensen NR, Devanathan N, Dimaras H, Corson TW. The potential of aqueous humor sampling in diagnosis, prognosis, and treatment of retinoblastoma. *Invest Ophthalmol Vis Sci*. 2024;65(1):18. <https://doi.org/10.1167/iov.65.1.18>

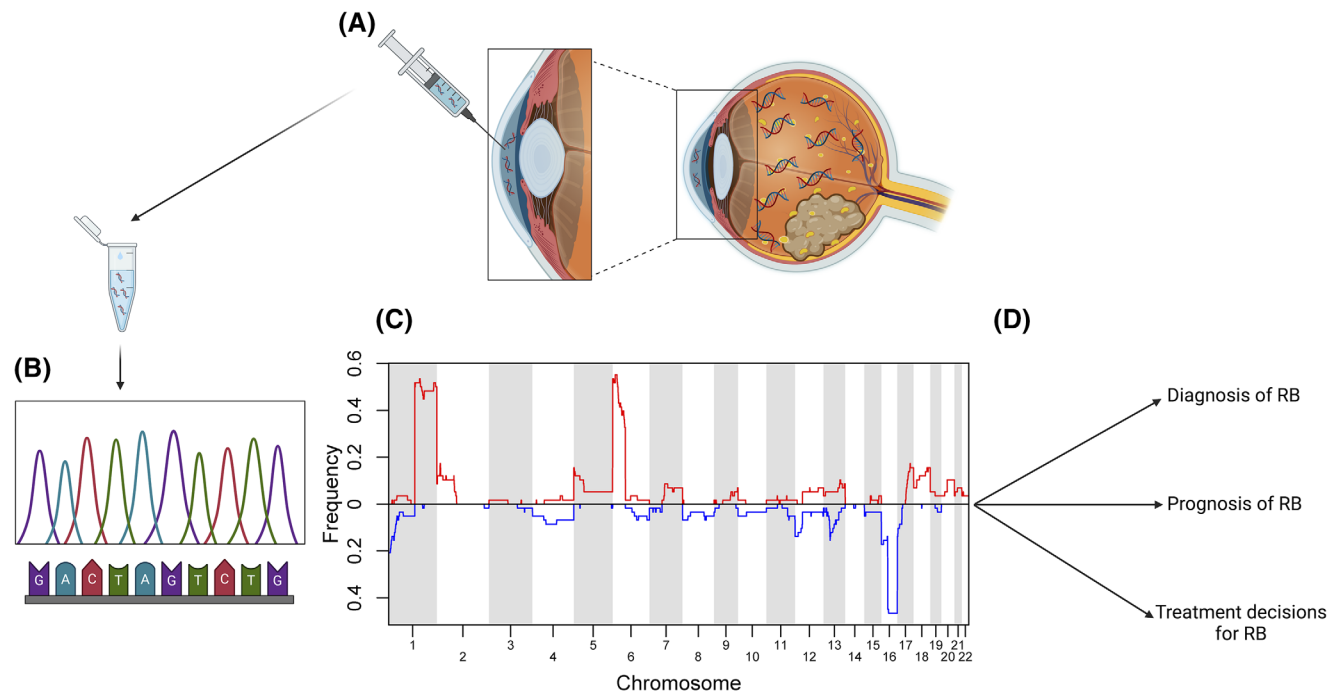
Retinoblastoma (RB) is a rare malignant tumor that arises in the developing retina in one or both eyes of children. Pathogenic variants of the *RB1* tumor suppressor gene drive the majority of germline and sporadic RB tumors. Considering the risk of tumor spread, the biopsy of RB tumor tissue is contraindicated. Advancement of chemotherapy has led to preservation of more eye globes. However, this has reduced access to tumor material from enucleation specimens. Recently, liquid biopsy of aqueous humor (AH) has advanced the RB tumor- or eye-specific genetic analysis. In particular, nucleic acid analysis of AH demonstrates the genomic copy number profiles and *RB1* pathogenic variants akin to that of enucleated RB eye tissue. This advance reduces the previous limitation that genetic assessment of the primary tumor could be done only after enucleation of the eye. Additionally, nucleic acid evaluation of AH allows the exploration of the genomic landscape of RB tumors at diagnosis and during and after treatment. This review explores how AH sampling and AH nucleic acid analysis in RB patients assist in diagnosis, prognosis, and comprehending the pathophysiology of RB, which will ultimately benefit individualized treatment decisions to carefully manage this ocular cancer in children.

**Keywords:** retinoblastoma, aqueous humor, biomarker, circulating tumor DNA, nucleic acid

Each year, an estimated 8000 new cases<sup>1-4</sup> of retinoblastoma (RB) are diagnosed worldwide. Identifying early signs of RB like leukocoria,<sup>4</sup> signaled by an absent red reflex in childhood, and offering rapid intervention can help confer an improved prognosis. Late signs of the disease include manifestations of orbital extension,<sup>5</sup> such as proptosis and iris neovascularization. Tumors have a poorer prognosis when identified at this stage. Although RB is ostensibly a clinical diagnosis, patients should also undergo confirmatory indirect ophthalmoscopy with dilation, a full fundoscopic examination under general anesthesia to determine tumor burden, and magnetic resonance imaging to assess for optic nerve or intracranial invasion<sup>4</sup> or trilateral disease involving the pineal gland.<sup>6</sup> Enucleation remains the first-line therapy worldwide, often curing the disease,<sup>4</sup> and histopathological analysis of the enucleated eye helps identify high-risk features such as optic nerve or choroidal invasion, or to obtain further information for possible intervention

with more aggressive therapeutic modalities, including intravenous chemotherapy<sup>7</sup>

RB usually initiates with loss of both alleles of the *RB1* gene, although a subset of patients are characterized by *MYCN* amplification in the absence of *RB1* pathogenic variants/mutations.<sup>8</sup> These driver events, termed mutations 1 and 2 (M1 and M2) are followed by further genetic perturbations (M3...Mn).<sup>9</sup> These include chromosomal somatic copy number alterations (SCNAs), like gains of 6p, 2p (including the *MYCN* locus), and 1q and/or deletions at 13q and 16q.<sup>10</sup> These SCNAs have gained attention as they inactivate tumor suppressors and activate oncogenes important for RB progression.<sup>10</sup> Additional epigenetic modifications, like aberrant DNA methylation (hypermethylation of tumor suppressor genes via transcriptional activation of DNA methyltransferase 1 [*DNMT1*]), microRNA dysregulation, and histone deacetylation (induced by histone deacetylases that cause transcriptional activation



**FIGURE.** Overview of aqueous humor (AH) liquid biopsy and genetic screening in retinoblastoma (RB) patients. **(A)** Collection of AH from the anterior aqueous chamber of an eye with RB (illustrating the features of tumor growth and vitreous seeding [yellow spots]) through corneal paracentesis allows extraction of cell-free DNA (cfDNA) containing circulating tumor DNA (ctDNA) of RB tumor origin. **(B)** Genomic analysis (amplification and sequencing) of cfDNA identifies *RB1* pathogenic variants and copy number alterations. **(C)** Somatic copy number alteration (SCNA) analysis reveals recurrent chromosomal gains (red: 1q, 2p and 6p) and losses (blue: 16q) along with other SCNAs that are not highly recurrent. **(D)** The outcome of genetic analyses may aid diagnosis of RB via *RB1* genomic alterations and other changes including *MYCN* amplification, prognosis of RB by SCNA biomarker detection, and in making personalized treatment decisions for RB patients. Panel C reproduced from Kim ME, Polski A, Xu L, et al. Comprehensive somatic copy number analysis using aqueous humor liquid biopsy for retinoblastoma. *Cancers*. 2021;13:3340. © 2021 by the authors. Available under the Creative Commons Attribution (CC BY) license.

of pro-growth genes),<sup>11–13</sup> further contribute to tumor growth.

Because the *RB1* pathogenic variant is heritable in 40% of patients, it is necessary to assess the germline status of a patient's pathogenic variant via genetic testing of peripheral blood to offer (if needed) surveillance for further RB tumors in childhood, and life-long surveillance for osteosarcoma, melanoma, and other *RB1*-associated malignancies.<sup>14–16</sup> Screening of possibly affected family members is also needed. Patients with a germline *RB1* pathogenic variant (M1 in all cells) usually develop multifocal, bilateral (or even trilateral) disease, while patients with sporadic disease (both M1 and M2 occurring in a single susceptible cone precursor cell)<sup>17</sup> have a unilateral, unifocal tumor. Current therapeutic interventions include focal laser- or cryotherapy, systemic intravenous chemotherapy, intraocular artery chemotherapy, and intravitreal chemotherapy (IVIc)<sup>7</sup> for individualized treatments. IViC allows for successful treatment of traditionally challenging vitreous seeding of tumor cells.<sup>18,19</sup>

The rise of globe-sparing therapies has decreased the number of enucleated RB tumors available for histopathological, biochemical and genetic profiling,<sup>20</sup> thereby encouraging advances in liquid biopsy<sup>21</sup> practices that are inspired by the possibility of harvesting genomic and proteomic information from aqueous humor (AH) sampling.<sup>22</sup> Because fluid is introduced to the eye during IViC therapy, AH is usually removed to help normalize intraocular pressure. Note, however, that AH sampling at time of diagnosis or

treatment is not feasible for all RB eyes given the challenge of chamber shallowing from large-sized tumors and increased pressure in some advanced eyes.<sup>23</sup> A number of proteins and metabolites have been assessed as AH biomarkers in RB detection. However, nucleic acids are the key molecules wherein chromosomal variations occur, which are known to drive RB, and can be readily analyzed with high sensitivity tools. Hence, this review focuses on the role of how analyzing nucleic acids obtained from AH sampling could inform the diagnosis, prognosis, and treatment of RB.

Many tumor types can be evaluated through direct tumor sampling. However, this has been historically contraindicated in RB because of the risk of extraocular or vitreous seeding occurring as a consequence of disrupting the integrity of the globe by introducing a needle.<sup>18,24</sup> In fact, not only has direct tumor sampling been contraindicated in RB because it might cause extraocular extension, but even IViC of patients with RB undergoing treatment was also previously avoided. This practice was challenged with the development of safe IViC treatment protocols with injection preceded by paracentesis (although IViC can still be contraindicated in eyes with retinal detachment).<sup>19,25</sup> As AH sampling grows in interest, there are three questions that can help evaluate its importance: Can AH sampling aid in diagnosis of RB? Can AH sampling aid in prognosis of RB? Can AH sampling aid in treatment decisions for RB? (Fig.). We discuss these questions along with future prospects for AH analysis in this cancer.

## CAN AH SAMPLING AID IN DIAGNOSIS OF RB?

Although blood sampling has served as a source of circulating tumor DNA and tumor cells,<sup>26</sup> the blood to ocular barriers makes this sampling less favorable in RB compared to other cancers as it identifies only minimal tumor fraction (TFx) in the blood, thus limiting the identification of prognostic biomarkers of RB. To circumvent this concern, AH liquid biopsy has been found as an ocular-specific substitute since it is a robust source of cell-free DNA (cfDNA).<sup>22,23</sup> A summary of AH nucleic acid sampling studies to date is provided in the Table. A case study by Berry et al.<sup>22</sup> laid the groundwork for evaluation of nucleic acids by establishing that there is a sufficient amount of tumor DNA for sampling and evaluation included in the cfDNA within the AH (100 µL) extracted via corneal paracentesis. A follow-up study<sup>27</sup> evaluated AH sampling because the patients' eyes were either undergoing treatment or enucleation. This evaluation pioneered the identification of recurring SCNAs in AH, which were seen at a higher rate (92%) in enucleated eyes compared to salvaged eyes (38%). This study also revealed an accurate match of chromosomal gains and losses between the tumor and AH in 11 of 13 eyes.<sup>27</sup> However, it can be claimed that the AH DNA profile matched the tumor in all 13 eyes when considering that some of these tumors likely exhibited a heterogenous mixture of tumor-derived DNA from each tumor clone. This group later showed 93% and 97% concordance in the genomic profiles acquired from cfDNA of AH and matching RB tissues for two eyes that were enucleated.<sup>28</sup>

Further studies have proven the diagnostic capabilities of nucleic acids within AH. The AH-derived DNA analysis of RB eyes and matched blood samples of patients demonstrated the presence of tumor derived SCNAs present only in AH, and relatively higher yield of cfDNA in AH than in blood samples. SCNA profiles of 11/20 patients were consistent with those common in RB while 0/20 of the blood samples exhibited SCNA profile consistency to RB, highlighting the superiority of AH aiding diagnosis over the conventional peripheral blood sample testing. Seven of those 20 AH samples were extracted at time of diagnosis with the other 13 at time of treatment, indicating the ease of tumor genome (mutational) analysis during the course of RB.<sup>29</sup> A study by a separate group evaluated *RB1* pathogenic variants in three enucleated eyes of RB ( $n = 3$  patients) and corresponding AH and blood samples from the same patients.<sup>30</sup> Sequence analysis performed in RB tumor and AH of these three eyes revealed deletion of *RB1* promotor to exon 23, and identification of two heterozygous nonsense variants of *RB1* in two patients, denoting the lack of a germline *RB1* pathogenic variant in these patients. The third patient exhibited heterozygous substitution on the first allele and loss of heterozygosity on the second allele, implicating the existence of a germline *RB1* pathogenic variant. Of these three patients, the RB tumor and AH were concordant for all three patients; however, the blood sampling only matched in one of the three individuals (patient three), consistent with a germline variant.

Building on this, whole genome sequencing of AH samples allowed for 100% recognition of pathogenic variants for all RB patients ( $n = 7$  eyes of six RB patients) in one study<sup>31</sup> and in nine of 10 paired AH-tumor samples in another study.<sup>32</sup> In this latter work, even AH of patients undergoing active IViC could be used to detect a single nucleotide variant (SNV) in *RB1* and a

region of loss of heterozygosity in two patients, despite an overall reduction in cfDNA in eyes undergoing therapy, thereby indicating that the majority of cfDNA in the AH is tumor-derived.

Perhaps one of the largest benefits of AH as compared to blood DNA analysis is the ability of AH to aid in detection of low-level germline *RB1* mosaicism, which may be overlooked in the standard peripheral blood testing of RB diagnosis.<sup>31,33</sup> A workflow using AH nucleic acids to aid in diagnosis allows for identification of both *RB1* pathogenic variants in patients with both heritable and non-heritable disease. Comparing this workflow to blood evaluation shows the power of AH sampling, as blood evaluation can currently only identify germline *RB1* variants.<sup>28</sup>

The AH liquid biopsy has become a powerful tool for identifying cfDNA, analysis of which detects SCNAs, as well as pathogenic variants in the *RB1* gene. SCNA identification in blood samples poses considerable challenges because of low TFx and an inability to correlate the SCNAs in each eye's tumor(s). AH based analysis can detect SCNAs that are specific for each eye to aid in prognostication (see next section), particularly valuable in the 40% of patients with bilateral disease.<sup>28,34</sup> That said, a recent study<sup>35</sup> demonstrated the identification of somatic *RB1* pathogenic variants in plasma of patients with an advanced intraocular tumor; however, there have been no further reports extending this finding. Also, Sirivolu et al.<sup>36</sup> documented the existence of a 6p gain SCNA in the TFx of both AH and blood samples of a single RB patient, perhaps suggestive of high levels of TFx in the blood when RB tumors are very large. Nonetheless, the use of AH nucleic acid analysis remains more sensitive than blood for detecting RB SCNAs.<sup>29</sup>

A common limitation is that not every RB eye will have detectable SCNAs. However, a possible solution is evident in promising studies evaluating methylation analysis of AH-derived DNA. To that end, a proof-of-concept study showed a substantial detection of methylated transcription factor AP2-alpha gene (*TFAP2A*) in cfDNA of AH and RB tissues, higher than in AH and retinal tissues from individuals without RB as detected by methylation specific PCR; intriguingly, the levels of methylated *TFAP2A* in AH were consistent with those of RB tissues.<sup>37</sup> *TFAP2A* is a signaling nexus in tumor progression that promotes tumor stemness and triggers epithelial mesenchymal transition (EMT) and metastasis via augmenting the expression of various oncogenes.<sup>38</sup> Plus, epigenetic DNA methylation profiling investigated via targeted bisulfite sequencing uncovered DNA hypermethylation signatures of various promoters in the AH cfDNA including *RB1*, *AXIN2*, *FGFR1* (fibroblast growth factor receptor 1), *GSTA4* (glutathione S-transferase alpha 4), *IL1R2* (interleukin 1 receptor 2), *STK19* (serine/threonine kinase 19), and *TFF1* (trefoil factor 1), and DNA hypomethylation of the *MYCN* and *SYK* promoters in corroboration with RB tumor methylation signatures.<sup>39</sup> The mechanisms leading to these aberrant methylation patterns remain unknown.

Another important limitation is that to date, AH sampling has not been reported for narrowing a differential diagnosis for which RB is included on the differential analysis (in those rare patients where diagnosis is ambiguous). However, AH sampling has been successfully used for unusual presentations such as diffuse infiltrating RB<sup>40</sup> and anterior disease.<sup>41</sup> Further such use in unclear cases will be the key final step in establishing the diagnostic potential of this technology for RB.

TABLE. Chronological Listing of Retinoblastoma Genomic Studies Using AH Liquid Biopsy

Analysis of AH	Main Outcome of the Study	Number of AH/Tumor/Blood Samples	Number of Eyes/Patients	Reference
Isolation of cfDNA from the AH of RB patients and evaluation of nucleic acids by shallow whole genome sequencing along with SCNA profiling	An adequate concentration of nucleic acids (DNA, RNA and microRNA) was seen in the AH samples, and chromosomal SCNAs were consistent with tumor DNA	n = 6 AH samples; 4 samples collected prior to intravitreal melphalan treatment and 2 from later enucleation	3 RB eyes	22
SCNA detection in the RB tumor-derived cfDNA of the AH using whole genome sequencing (shallow)	Chromosome 6p gain was detected in the AH of enucleated eyes (77%, n = 13 eyes) and salvaged eyes (25%, n = 16 eyes)	n = 63 AH samples	29 eyes of 26 RB patients	27
SNV detection in the AH cfDNA of RB patients who underwent enucleation and those undergoing IViC	SNVs and exonic (E6) deletion of <i>RB1</i> and loss of heterozygosity regions were detected in AH cfDNA with similarity to tumor DNA in the enucleated eyes. SNVs were detected in one patient and loss of heterozygosity in another patient undergoing IViC	n = 12 AH samples; 10 extracted post enucleation and 2 during IViC	12 RB eyes; 10 enucleated eyes and 2 eyes of patients undergoing IViC	32
Evaluation of germline <i>RB1</i> genomic profile/stability in the AH of RB patients	Higher number of total and recurrent RB SCNAs correlated with the age of RB patients rather than with patients' hereditary status and clinical grouping of RB tumor	n = 115 AH samples	54 eyes of 50 RB patients; 23 hereditary RB and 27 non-hereditary RB patients	47
<i>RB1</i> variant and SCNA detection in RB AH	SCNA were detected in 4 out of 7 AH and 4 tumor samples and focal amplification of <i>MYCN</i> (1 sample) and <i>RB1</i> deletion (1 sample); similar <i>RB1</i> variant identification as that of RB tumor and blood (M1 – two germline <i>RB1</i> SNVs and copy number variants, and M2 – four <i>RB1</i> SNVs)	n = 7 AH samples and 4 matched tumor samples	7 eyes of 6 RB patients	31
Therapy oriented longitudinal assessment of TFx and SCNA of AH cfDNA	Marked changes (increase or decrease) in the TFx and SCNA amplitude corresponded to progression or regression of RB in response to IViC	n = 78 AH samples (patients underwent 3 or more AH liquid biopsies)	20 eyes of 20 RB patients	53
SCNA identification in the AH cfDNA of RB patients (salvaged and enucleated eyes) via shallow whole genome sequencing	Commonly recurrent SCNAs such as 1q, 2p, and 6p chromosomal gains and 13q and 16q losses, with predominant occurrence of 6p gain, seen in the enucleated eyes over salvaged eyes	n = 116 AH samples	50 eyes of 46 RB patients	44
<i>RB1</i> gene profiling by hybridization and sequencing	Biallelic deletion of entire <i>RB1</i> gene confirmed RB diagnosis in a hypertensive uveitis patient	n = 1 AH sample	1 RB patient	41
Comparative analysis of cfDNA extracted from blood and AH samples to assess SCNA by shallow whole genome sequencing	Consistent SCNA profiles of RB were found in 11 out of 20 AH cfDNA samples while none of the cfDNA of blood samples revealed RB SCNAs	n = 20 AH and matched blood samples	17 RB patients	58



TABLE. Continued

Analysis of AH	Main Outcome of the Study	Number of AH/Tumor/Blood Samples	Number of Eyes/Patients	Reference
Whole genome analysis of cfDNA isolated from RB AH to validate SCNAs of RB	Highly and non-highly recurrent SCNAs of RB were identified, and differing prevalence of 20q gain and 8p loss between primary and secondary enucleations, plus heightened chromosomal instability	n = 68 AH samples	68 eyes of 64 RB patients	42
Exploration of inter-eye genomic profiles using AH cfDNA of a bilateral patient	1q gain, 13q and 16q loss with reduced AH TFx seen in the right eye which had three intravitreal melphalan treatments while the left eye displayed 6p gain and 13q loss with an elevation of TFx	n = 5 AH (3 right eye and 2 left eye) samples	1 RB patient	43
Genome-wide SCNA detection in AH samples by sequencing and resequencing to detect <i>RB1</i> and <i>MYCN</i>	RB-specific genomic information including SCNAs of RB seen in 5 out of 7 AH samples, and SNVs of <i>RB1</i> gene in 5 out of 7 AH samples	n = 7 AH samples extracted at time of diagnosis	6 RB patients	28
Genome-wide methylation screening	Increased level of methylated <i>TFAP2A</i> seen in AH of RB patients vs. AH of non-RB patients, consistent with the levels noted in RB tissues	n = 15 AH from RB and 5 AH samples from non-RB patients	15 RB and 5 non-RB patients	37
A single analysis of AH cfDNA via next-generation sequencing with the combinational use of unique molecular identifiers	Highly sensitive detection of a panel of RB-relevant genes including <i>RB1</i> , <i>MYCN</i> , <i>MED4</i> , and <i>TP53</i> variants, SNVs, and microsatellites	n = 11 AH samples	11 RB patients	62
Genomic analysis of RB AH sample	Two somatic <i>RB1</i> variants identified, c.1589_1590del and c.2330dupC in the AH of an advanced unilateral RB patient	n = 1 AH sample	1 RB eye that underwent primary enucleation	36
DNA methylation profile investigation in the cfDNA of paired AH and RB tumors	Detected DNA methylation signatures in the RB AH with a pronounced similarity to RB tumors, in addition to distinct prognostic markers of DNA methylation in salvaged eyes and eyes that had therapy failure and were eventually enucleated	n = up to 10 AH samples and matched RB tumors	12 RB patients	39
Measurement of mitochondrial to nuclear DNA ratio in RB AH, and copy number analysis of nuclear and mitochondrial genes	Substantially decreased mitochondrial to nuclear DNA ratio seen, with elevation in the copy number of <i>GAPDH</i> and <i>B4GALNT1</i> (conserved nuclear genes) in RB AH over controls while no change in the copy number of <i>MT-ATP6</i> (mitochondrial gene) between RB and controls	n = 42 RB AH samples, and 11 non-RB AH samples	25 RB patients, and 11 control (non-RB) patients who had no other cancer	49

TABLE. Continued

Analysis of AH	Main Outcome of the Study	Number of AH/Tumor/Blood Samples	Number of Eyes/Patients	Reference
Comparable detection of germline <i>RB1</i> pathogenic variant in RB AH	Identified <i>RB1</i> promotor deletion on exon 3 (patient 1), and dual <i>RB1</i> nonsense pathogenic variants with heterozygosity (patient 2), and point mutation on allele 1 with loss of heterozygosity on allele 2 (patient 3) in AH, consistent with RB tumor	n = 3 AH and matched tumor samples	n = 3 eyes of 3 RB patients	30
Nucleic acid and protein quantification of RB AH samples	AH samples at diagnosis produced a richer yield of nucleic acids such as ssDNA, dsDNA, microRNA, and protein than samples collected during treatment. Samples from Groups D and E eyes had elevated concentrations relative to Groups B and C. Samples from Group A eyes showed undetectable analytes	n = 128 RB AH samples, and n = 14 control AH samples	62 eyes of 55 RB patients, and 14 non-RB, control eyes	59
AH cfDNA isolation and shallow whole genome sequencing to assess various SCNAs	2p and 7q gains and 19q loss along with additional recurrent signatures including 1q and 6p gains, 16q loss, and non-recurrent 17q gain and 19q loss were detected	n = 58 AH samples; 41 samples extracted post enucleation and 17 before IViC	58 RB patients	46
Simultaneous genomic profile analysis of SCNAs and SNVs in both AH and tumor samples of RB by targeted sequencing approach	Detected SCNAs in 100% AH samples with 90% of them identified as recurrent SCNAs of RB. Plus, demonstration of the presence of RB-SCNAs in 81.8% tumor samples. Parallel identification of nine SNVs including those of <i>RB1</i> , <i>MYCN</i> , <i>BCOR</i> and <i>CREBBP</i> ; 89% of these SNVs were shared among the AH and tumor samples	n = 11 AH and matched tumor samples	11 RB patients	61
AH cfDNA analysis of unilateral, diffuse infiltrating retinoblastoma patients using a targeted next-generation sequencing approach	Uncovered somatic alterations of the <i>RB1</i> gene in both alleles which were absent in the germline DNA assessed in peripheral blood and buccal mucosa	n = 2 AH samples	2 RB patients	40

AH, aqueous humor; cfDNA, cell-free DNA; ctDNA, circulating tumor DNA; IViC, intravitreal chemotherapy; RB, retinoblastoma; SCNA, somatic copy number alteration; SNV, single-nucleotide variant; Tfx, tumor fraction.  
Note that some patients are reported across multiple studies.

CAN AH SAMPLING AID IN PROGNOSIS OF RB?

Although not yet conclusive, there is evidence that AH sampling can reflect the status of the tumor and the tumor burden. Evaluation of eyes that had undergone enucleation showed that the presence of two key factors could potentially provide prognostic value. One of them is a specific RB SCNA, gain of 6p. This gain was more common in eyes that were enucleated compared to eyes that were salvaged, with the median amplitude of 1.47 (enucleated eyes) versus 1.07

(salvaged eyes).<sup>27</sup> Furthermore, patients with 6p gain and patients with any other SCNA showed 2.14 and 1.17 times, respectively, higher chances of enucleation than salvage of the eye<sup>27</sup> and 6p gain also directly correlated with class of the vitreous seeds, categorized based on their morphologies as class 1 (dust), class 2 (sphere), and class 3 (cloud).<sup>42</sup> Intriguingly, in an inter-eye genomic analysis of a patient with bilateral RB, the left eye, which had marked 6p gain in the AH cfDNA (amplitude 1.8), was subjected to enucleation after IViC with melphalan treatment failure, while the

right eye, which had no 6p SCNA in the AH cfDNA, was salvaged following three courses of IViC with melphalan.<sup>43</sup> Subsequent follow-up reinforced these findings: in 50 eyes of 46 patients, 6p gain in the AH was seen in 17 of 23 enucleated eyes and only 8 of 27 salvaged eyes. This translated to an almost 10-fold increased odds of enucleation for eyes with 6p gain.<sup>44</sup> Interestingly, 6p gain also associated with high-risk histopathologic features in enucleated eyes.<sup>45</sup>

A second possible prognostic factor is *MYCN* amplification. Eyes with *MYCN* amplification-driven RB may feature larger, more aggressive tumors more likely to invade the optic nerve than the heritable *RB1*<sup>-/-</sup> counterpart (although *MYCN* lower-copy gain or even amplification is also commonly seen in *RB1* mutant tumors as well since the *MYCN* locus lies in the minimal common region of 2p gain).<sup>8</sup> Therefore the ability to detect *MYCN* amplification along with 6p gain could help to provide an accurate prognosis. These two possible prognostic indicators, 6p gain and *MYCN* amplification, are both available by sampling AH. Initially these measurements of SCNA (6p gain) and *MYCN* amplification were all noted in enucleated eyes, which created the question of whether these prognostic abilities were only theoretical. However, subsequent studies that measured 6p gain and *MYCN* amplification at time of diagnosis removed this concern.

In a retrospective study, four out of 68 RB eyes presented with *MYCN* amplification with or without 6p gain and other SCNAs including 1q gain and losses of 16p and 16q; all were enucleated (these *MYCN* amplified tumors did not present with histology consistent with *MYCN*-driven RB).<sup>42</sup> This study also revealed increased genomic instability in secondary versus primary enucleation samples, and uncommon SCNAs, 20q gain and 8p loss, only in secondary enucleation samples. Also, in a prospective study, two eyes (out of seven) were secondarily enucleated because of therapy failure, and these had either *MYCN* amplification or 6p gain.<sup>28</sup> Another recent study of 58 AH samples taken at enucleation or time of IViC flagged 19q loss as common in advanced-stage patient samples and associating with high-risk pathologic features, and 2p (presumably including the *MYCN* locus, but this was not specified) and 7q gain as each associated with enucleation.<sup>46</sup> This intriguing evidence further strengthens the claim that AH nucleic acid analysis is capable of detecting 6p gain, *MYCN* amplification, and other SCNAs that could be prognostic.

Other than the key factors discussed above, other diverse findings add prognostic values to RB AH analysis. AH SCNAs in RB patients increased with the age of the tumor/patients' age at diagnosis but did not vary with heritable status<sup>47</sup>; it is not surprising that SCNAs might increase over time as tumor progresses. The identification of DNA methylation signatures associated with prognosis in the AH cfDNA of salvaged and enucleated eyes with RB, as described above, also underscores the capability of AH analysis in tracing potential prognostic markers of DNA methylation during therapy.<sup>39</sup> A longitudinal study of 25 RB patients quantitatively measured conserved nucleic acid sequences of nuclear and mitochondrial genes in the AH during IViC, wherein markedly increased copy counts of nuclear genes *GAPDH* and *B4GALNT1* (a ganglioside synthase previously identified as a putative biomarker of GD2-positive phenotype in triple negative breast cancer [TNBC] vs. non-TNBC samples<sup>48</sup>) and unaltered copy counts of *MT-ATP6* (mitochondrial gene) were seen in AH from RB patients with progressive disease relative to progression-free patients and controls.<sup>49</sup> Finally,

the secretory protein associated with RB metastasis, TFF1, has been detected in the AH, where it is also correlated with increased metastasis risk.<sup>50</sup> Although not a nucleic acid, this novel biomarker bears mentioning given its prognostic potential.<sup>51,52</sup> These approaches of AH analysis might add prognostic values when routine funduscopy observation is challenging due to obstructed views.

## CAN AH SAMPLING AID IN TREATMENT DECISIONS FOR RB?

AH sampling has promising potential to aid in diagnosis and prognosis of patients suffering from RB. However, AH sampling could also aid clinicians in key steps to guide treatment plans. As noted above,<sup>22</sup> AH DNA could indicate the importance of enucleation in situations where there is presence of 6p gain or *MYCN* amplification. One of the earliest studies investigating cfDNA within AH proved its ability to predict eye salvage,<sup>27</sup> whereas a longitudinal study ( $n = 20$  eyes of 20 patients) that featured serial AH sampling (at least three) showed that TFX increase or decrease correlated with disease progression or regression respectively. Specifically during IViC, elevated TFX (at least/over 15%) in comparison to baseline and higher SCNA fraction were correlated with higher chances of disease progression, with the converse associated with regression.<sup>53</sup> Dramatically, a 15% increase in TFX conferred a 90-fold increased odds of progression, implying the concurrence of longitudinal changes in the TFX and SCNA to the therapeutic response. Consistent with these examples of AH sampling aiding treatment decisions, cfDNA content was reduced in eyes undergoing IViC compared with naïve eyes in another study.<sup>32</sup> Similarly, in the genome copy study mentioned above, *GAPDH* copy counts decreased in patients responding to chemotherapy, while one non-responder retained high *GAPDH*.<sup>49</sup> AH sampling and AH nucleic acid evaluation might therefore be used to assess the status of the tumor during the course of RB management. Since evidence of using AH nucleic acids for treatment response is not yet so well developed, other AH biomolecules may also offer value. For instance, we recently showed that AH vascular endothelial growth factor A (VEGF-A) levels could be a biomarker of RB vitreous seed treatment response in a rabbit xenograft model and in eyes of human patients undergoing IViC with melphalan.<sup>54</sup> This finding revives the question of whether anti-VEGF agents may have therapeutic relevance in RB.<sup>55,56</sup>

## POTENTIAL PROMISE, CHALLENGES, AND FUTURE DIRECTIONS

How might AH sampling fit into a clinical practice guideline? AH will likely have a future role for the inclusion of molecular biomarkers in the assessment of therapeutic response.<sup>57</sup> AH sampling could be used at time of diagnosis to assist in establishing diagnosis, particularly to understand the cause of RB (*RB1* germline variant vs. *RB1* sporadic variant vs. *MYCN* amplification) and its prognosis. This may be followed by repeated and periodic AH sampling during IViC treatment, because routine chemotherapies often require multiple visits. Such sampling could provide insight into tumor progression or remission; moreover, shifts in the pattern of SCNAs during treatment can potentially be monitored, which could support assessment of prognostic outcomes.

However, eyes with advanced tumors that should be enucleated at diagnosis would not undergo AH sampling, due to the unnecessary risk this adds, without added benefit as primary tumor material for genetic analysis is available from the enucleated eyes. At the other end of the severity spectrum, we do not yet know how useful AH biopsies from eyes with small tumors are, as these tumors are not treated with IViC and they may not yield enough cfDNA for analysis. This limitation also raises the broader question of whether AH sampling should be done as a standalone procedure on eyes that are not undergoing IViC. A careful risk-benefit analysis of this will depend on the outcomes of future prospective studies, and patient (parent/guardian) preferences will have to be assessed as well.

We anticipate that prognostication will become more accurate as more studies are done, including detection of genetic alterations beyond *RB1* inactivation, such as focal *MYCN* amplification and amplification of other oncogenes (for instance transcription factor *MDM4* and kinase *RAF1*) in larger patient pools.<sup>58</sup> Further studies investigating SNVs that are only found in a subset of RB tumors, such as those in transcription factors *BCOR* or *CREBBP* will enhance clinicians' ability to provide personalized, accurate genetically-informed prognosis not only for each patient and but also for each eye.<sup>28</sup> Again, if AH sampling becomes incorporated into standard care and as more studies examine its role, we anticipate that TFX may help guide clinicians' treatment decisions since TFX has been validated as a clinically relevant biomarker of RB therapeutic response.<sup>53</sup>

One challenge to AH sampling is limitations on material: how much information can be gathered from a single AH sample? One 100  $\mu$ L AH sample currently suffices for detection of SCNA via sequencing, identification of *RB1* variant profiles, and measurement of TFX.<sup>51</sup> Fortunately, recent advancements have provided evidence that 1  $\mu$ L of AH allows measurements of various circulating analytes such as microRNA, double- and single-stranded DNA, and protein in samples collected at diagnosis, during, and post treatments<sup>59</sup>; this evidence eases the concern on material limitation, although small tumors (Group A eyes in the International Intraocular RB Classification<sup>60</sup>) in this study proved unreliable for yielding usable analytes. Another limitation is the need for more than one AH cfDNA analysis to assess SCNA and SNVs individually, which are time consuming and could cause diagnostic delay. To address this concern, a recent study presented a targeted sequencing approach over whole genome sequencing, enabling the analysis of AH cfDNA in demonstrating contemporaneous screening of both SCNA and SNVs from a single sample.<sup>61</sup> Another combined analysis of AH cfDNA performed via next-generation sequencing coupled with the use of unique molecular identifiers (molecular barcodes) offered identification of *RB1*, *MYCN*, *MED4* (part of the mediator transcriptional regulatory complex), and *TP53* variants, SNVs, and microsatellites with high sensitivity.<sup>62</sup> Such screening methods will not only help improve quicker diagnosis but also will aid in treatment decisions to potentially enhance better outcomes of RB management.

Additionally, the sensitivity and accuracy of AH derived analyses may inform management of RB in the future, aiding treatment decisions for RB patients given the information of patient/eye specific genomic landscape,<sup>28</sup> if and when treatments targeted to specific genomic alterations are developed. Understanding RB-specific SCNAs will not only offer identification of prognostic biomarkers, but also ultimately

gene/SCNA-specific therapeutic interventions. These could include potential therapies targeting the transcription factors *E2F3* or *DEK*, as these genes lie in the minimal region of gain on 6p<sup>44</sup> and are oncogene candidates in RB.<sup>63,64</sup> We anticipate that these and other pathways associated with RB tumorigenesis, such as oncogene candidates in commonly-gained 1q (*KIF14*, *MDM4*) and tumor suppressor gene candidates in commonly-lost 16q (*CDH11*),<sup>10</sup> may be identified as possible therapeutic targets. AH sampling will help us understand the multifactorial nature of the disease and thereby offer target-specific treatment modalities.

Aside from genetic markers in RB AH, an array of proteins and small-molecule metabolites are also dysregulated in RB AH. A thorough discussion of these is beyond the scope of this review, but readers are directed to the review by Ghiam et al.,<sup>65</sup> which covers known protein and metabolite markers including lactate dehydrogenase (LDH) and enolase/neuron-specific enolase (NSE) at elevated levels, survivin with a 62% sensitivity and 100% specificity to detect tumor, TGF- $\beta$ 1 with 100% sensitivity and 90% specificity, higher levels of uric acid and xanthine, and total protein content in AH. Adding to this, a recent proteomic analysis of RB AH biopsied at various stages explored a panel of 96 specific proteins. Many were upregulated in different stages including active vitreous and aqueous seeding and active and inactive RB with no seeding. They included apolipoproteins APOA4 and APOA1, ITIH4 (Inter-Alpha-Trypsin Inhibitor Heavy Chain 4), SERPINA6 and many others, which play essential roles in regulating multiple physiological functions.<sup>66</sup> Furthermore, a metabolomics analysis of RB AH revealed a panel of metabolic biomarkers including acetoacetic acid, aspartic acid, lactic acid, levulinic acid, norepinephrine, 1-pyrroline-5-carboxylic acid, and valine. These metabolites except levulinic acid and valine were found to be significantly overexpressed with progression of RB.<sup>67</sup> The underlying mechanisms for the involvement of these proteins and metabolites in RB pathogenesis and progression require further investigation in order to explore potential avenues for RB treatment. The next frontier is likely multiomic analysis: a state-of-the-art non-RB AH multiomics study recently identified hundreds of protein markers and their cellular origins through proteomics and single-cell transcriptomics together with an artificial intelligence (AI)-based approach. Such modern approaches have the potential to advance cellular and molecular level diagnosis and prognosis in RB screening and treatment responses.<sup>68</sup>

Although the rate of ocular salvage and improved visual outcomes of RB eyes have improved in recent years, AH genomic analyses hold promise to further maximize these and also guide treatment decisions to improve survival globally as sequencing technologies spread to low- and middle-income countries.<sup>69,70</sup> For now, analyses are done mainly on a research basis. Once further established and validated, cost effectiveness for patients and/or payers will also factor into widespread clinical deployment. Future prospects include the possibility of AH sampling in uveal melanoma<sup>71,72</sup> and potentially other ocular tumors. In the RB context, further assessment of non-coding RNAs in the AH holds promise, as does moving beyond nucleic acids to find novel protein biomarkers identified by proteomics<sup>66</sup> or small-molecule metabolites<sup>67</sup> as mentioned above. Long-term, RB outcomes may improve by allowing AH sampling to aid in confirming diagnoses, delineating prognoses, and enabling personalized therapeutics.



## Acknowledgments

Supported by Research to Prevent Blindness.

Disclosure: **A. Muniyandi**, None; **N.R. Jensen**, None; **N. Devanathan**, None; **H. Dimaras**, None; **T.W. Corson**, None

## References

- Seregard S, Lundell G, Svedberg H, Kivelä T. Incidence of retinoblastoma from 1958 to 1998 in Northern Europe: advantages of birth cohort analysis. *Ophthalmology*. 2004;111:1228–1232.
- Broadbent E, Topham A, Singh AD. Incidence of retinoblastoma in the USA: 1975–2004. *Br J Ophthalmol*. 2009;93:21.
- Kivelä T. The epidemiological challenge of the most frequent eye cancer: retinoblastoma, an issue of birth and death. *Br J Ophthalmol*. 2009;93:1129.
- Dimaras H, Corson TW, Cobrinik D, et al. Retinoblastoma. *Nat Rev Dis Primers*. 2015;1:15021.
- Honavar SG, Manjandavida FP, Reddy VAP. Orbital retinoblastoma: an update. *Indian J Ophthalmol*. 2017;65:435.
- Dimaras H, Corson TW. Retinoblastoma, the visible CNS tumor: a review. *J Neurosci Res*. 2019;97:29–44.
- Fabian ID, Onadim Z, Karaa E, et al. The management of retinoblastoma. *Oncogene*. 2018;37:1551–1560.
- Rushlow DE, Mol BM, Kennett JY, et al. Characterisation of retinoblastomas without *RB1* mutations: genomic, gene expression, and clinical studies. *Lancet Oncol*. 2013;14:327–334.
- Corson TW, Gallie BL. One hit, two hits, three hits, more? Genomic changes in the development of retinoblastoma. *Genes Chromosomes Cancer*. 2007;46:617–634.
- Thériault BL, Dimaras H, Gallie BL, Corson TW. The genomic landscape of retinoblastoma: a review. *Clin Exp Ophthalmol*. 2014;42:33–52.
- Philippe C, Busch M, Dünker N. Epigenetic control of trefoil factor family (TFF) peptide expression in human retinoblastoma cell lines. *Cell Physiol Biochem*. 2014;34:1001–1014.
- Chai P, Jia R, Li Y, et al. Regulation of epigenetic homeostasis in uveal melanoma and retinoblastoma. *Prog Retinal Eye Res*. 2022;89:101030.
- Fernandez-Diaz D, Rodriguez-Vidal C, Silva-Rodríguez P, et al. Applications of non-coding RNAs in patients with retinoblastoma. *Front Genet*. 2022;13:842509.
- Fletcher O, Easton D, Anderson K, Gilham C, Jay M, Peto J. Lifetime risks of common cancers among retinoblastoma survivors. *J Nat Cancer Inst*. 2004;96:357–363.
- MacCarthy A, Bayne AM, Brownbill PA, et al. Second and subsequent tumours among 1927 retinoblastoma patients diagnosed in Britain 1951–2004. *Br J Cancer*. 2013;108:2455–2463.
- Schonfeld SJ, Kleinerman RA, Abramson DH, Seddon JM, Tucker MA, Morton LM. Long-term risk of subsequent cancer incidence among hereditary and nonhereditary retinoblastoma survivors. *Br J Cancer*. 2021;124:1312–1319.
- Xu XL, Fang Y, Lee TC, et al. Retinoblastoma has properties of a cone precursor tumor and depends upon cone-specific MDM2 signaling. *Cell*. 2009;137:1018–1031.
- Kaneko A, Suzuki S. Eye-preservation treatment of retinoblastoma with vitreous seeding. *Jpn J Clin Oncol*. 2003;33:601–607.
- Munier FL, Beck-Popovic M, Chantada GL, et al. Conservative management of retinoblastoma: challenging orthodoxy without compromising the state of metastatic grace. “Alive, with good vision and no comorbidity”. *Prog Retinal Eye Res*. 2019;73:100764.
- Gerrish A, Jenkinson H, Cole T. The impact of cell-free DNA analysis on the management of retinoblastoma. *Cancers*. 2021;13:1570.
- Otandault A, Anker P, Al Amir Dache Z, et al. Recent advances in circulating nucleic acids in oncology. *Ann Oncol*. 2019;30:374–384.
- Berry JL, Xu L, Murphree AL, et al. Potential of aqueous humor as a surrogate tumor biopsy for retinoblastoma. *JAMA Ophthalmol*. 2017;135:1221–1230.
- Kim ME, Xu L, Prabakar RK, et al. Aqueous humor as a liquid biopsy for retinoblastoma: clear corneal paracentesis and genomic analysis. *JoVE*. 2021;(175):e62939.
- Francis JH, Abramson DH, Gaillard M-C, Marr BP, Beck-Popovic M, Munier FL. The classification of vitreous seeds in retinoblastoma and response to intravitreal melphalan. *Ophthalmol*. 2015;122:1173–1179.
- Munier FL, Soliman S, Moulin AP, Gaillard M-C, Balmer A, Beck-Popovic M. Profiling safety of intravitreal injections for retinoblastoma using an anti-reflux procedure and sterilisation of the needle track. *Br J Ophthalmol*. 2012;96:1084.
- Abramson DH, Mandelker D, Francis JH, et al. Retrospective evaluation of somatic alterations in cell-free DNA from blood in retinoblastoma. *Ophthalmol Sci*. 2021;1:100015.
- Berry JL, Xu L, Kooi I, et al. Genomic cfDNA analysis of aqueous humor in retinoblastoma predicts eye salvage: the surrogate tumor biopsy for retinoblastoma. *Mol Cancer Res*. 2018;16:1701–1712.
- Xu L, Kim ME, Polski A, et al. Establishing the clinical utility of ctDNA analysis for diagnosis, prognosis, and treatment monitoring of retinoblastoma: the aqueous humor liquid biopsy. *Cancers*. 2021;13:1282.
- Berry JL, Xu L, Polski A, et al. Aqueous humor is superior to blood as a liquid biopsy for retinoblastoma. *Ophthalmology*. 2020;127:552–554.
- Raval V, Racher H, Wrenn J, Singh AD. Aqueous humor as a surrogate biomarker for retinoblastoma tumor tissue. *JAPOS*. 2022;26:137.
- Xu L, Shen L, Polski A, et al. Simultaneous identification of clinically relevant *RB1* mutations and copy number alterations in aqueous humor of retinoblastoma eyes. *Ophthalmic Genet*. 2020;41:526–532.
- Gerrish A, Stone E, Clokie S, et al. Non-invasive diagnosis of retinoblastoma using cell-free DNA from aqueous humour. *Br J Ophthalmol*. 2019;103:721.
- Amitrano S, Marozza A, Somma S, et al. Next generation sequencing in sporadic retinoblastoma patients reveals somatic mosaicism. *Eur J Hum Genet*. 2015;23:1523–1530.
- Ghose N, Kaliki S. Liquid biopsy in retinoblastoma: a review. *Semin Ophthalmol*. 2022;37:813–819.
- Kothari P, Marass F, Yang JL, et al. Cell-free DNA profiling in retinoblastoma patients with advanced intraocular disease: an MSKCC experience. *Cancer Med*. 2020;9:6093–6101.
- Sirivolu S, Xu L, Warren M, et al. Chromosome 6p amplification detected in blood cell-free DNA in advanced intraocular retinoblastoma. *Ophthalmic Genet*. 2022;43:866–870.
- Zeng Q, Wang S, Tan J, Chen L, Wang J. The methylation level of *TFAP2A* is a potential diagnostic biomarker for retinoblastoma: an analytical validation study. *Peer J*. 2021;9:e10830.
- Jin C, Luo Y, Liang Z, et al. Crucial role of the transcription factors family activator protein 2 in cancer: current clue and views. *J Transl Med*. 2023;21:371.

39. Li H-T, Xu L, Weisenberger DJ, et al. Characterizing DNA methylation signatures of retinoblastoma using aqueous humor liquid biopsy. *Nat Commun.* 2022;13:5523.
40. Cassoux N, Malaise D, Lumbroso-Le-Rouic L, et al. Diffuse infiltrating retinoblastoma with anterior chamber involvement: conservative management and identification of RB1 alterations in aqueous humor. *Ocul Oncol Pathol.* 2023;9:96–100.
41. Kletke SN, Soliman S, Racher H, et al. Atypical anterior retinoblastoma: diagnosis by aqueous humor cell-free DNA analysis. *Ophthalmic Genet.* 2022;43:862–865.
42. Kim ME, Polski A, Xu L, et al. comprehensive somatic copy number analysis using aqueous humor liquid biopsy for retinoblastoma. *Cancers.* 2021;13:3340.
43. Wong EY, Xu L, Shen L, et al. Inter-eye genomic heterogeneity in bilateral retinoblastoma via aqueous humor liquid biopsy. *npj Precision Oncol.* 2021;5:73.
44. Xu L, Polski A, Prabakar RK, et al. Chromosome 6p amplification in aqueous humor cell-free DNA is a prognostic biomarker for retinoblastoma ocular survival. *Mol Cancer Res.* 2020;18:1166–1175.
45. Stålhammar G, Yeung A, Mendoza P, Dubovy SR, Harbour JW, Grossniklaus HE. Gain of chromosome 6p correlates with severe anaplasia, cellular hyperchromasia, and extraocular spread of retinoblastoma. *Ophthalmol Sci.* 2022;2:100089.
46. Luo Y, Xu M, Yang L, et al. Correlating somatic copy number alteration in aqueous humour cfDNA with chemotherapy history, eye salvage and pathological features in retinoblastoma. *Br J Ophthalmol.* bjo-2022-322866.
47. Polski A, Xu L, Prabakar RK, et al. Variability in retinoblastoma genome stability is driven by age and not heritability. *Genes Chromosomes Cancer.* 2020;59:584–590.
48. Sorokin M, Kholodenko I, Kalinovsky D, et al. RNA sequencing-based identification of ganglioside GD2-positive cancer phenotype. *Biomedicines.* 2020;8(6):142.
49. Cuadrado-Vilanova M, Burgueño V, Balaguer-Lluna L, et al. Follow-up of intraocular retinoblastoma through the quantitative analysis of conserved nuclear DNA sequences in aqueous humor from patients. *J Pathol Clin Res.* 2023;9:32–43.
50. Liu J, Ottaviani D, Sefta M, et al. A high-risk retinoblastoma subtype with stemness features, dedifferentiated cone states and neuronal/ganglion cell gene expression. *Nat Commun.* 2021;12:5578.
51. Busch MA, Haase A, Miroshnikov N, et al. TFF1 in aqueous humor—a potential new biomarker for retinoblastoma. *Cancers.* 2022;14:677.
52. Busch MA, Haase A, Alefeld E, Biewald E, Jabbarli L, Dunker N. Trefoil Family Factor Peptide 1-A new biomarker in liquid biopsies of retinoblastoma under therapy. *Cancers.* 2023;15:4828.
53. Polski A, Xu L, Prabakar RK, et al. Cell-free DNA tumor fraction in the aqueous humor is associated with therapeutic response in retinoblastoma patients. *Transl Vis Sci Technol.* 2020;9:30.
54. Daniels AB, Sishtla K, Bogan CM, et al. Aqueous VEGF-A levels as a liquid biopsy biomarker of retinoblastoma vitreous seed response to therapy. *Invest Ophthalmol Vis Sci.* 2023;61:E–abstract 2826.
55. Assayag F, Nicolas A, Vacher S, et al. Combination of carboplatin and bevacizumab is an efficient therapeutic approach in retinoblastoma patient-derived xenografts. *Invest Ophthalmol Vis Sci.* 2016;57:4916–4926.
56. Hou X, Cheng Y, Zhang Q, Liang J, Li X. Efficacy of intravitreal carboplatin plus bevacizumab in refractory retinoblastoma. [*Zhonghua yan ke za zhi*] *Chin J Ophthalmol.* 2015;51:126–129.
57. Berry JL, Munier FL, Gallie BL, et al. Response criteria for intraocular retinoblastoma: RB-RECIST. *Ped Blood Cancer.* 2021;68:e28964.
58. Afshar AR, Pekmezci M, Bloomer MM, et al. Next-generation sequencing of retinoblastoma identifies pathogenic alterations beyond *RB1* inactivation that correlate with aggressive histopathologic features. *Ophthalmology.* 2020;127:804–813.
59. Im DH, Pike S, Reid MW, et al. A multicenter analysis of nucleic acid quantification using aqueous humor liquid biopsy in retinoblastoma: implications for clinical testing. *Ophthalmol Sci.* 2023;3:100289.
60. Murphree AL. Intraocular retinoblastoma: the case for a new group classification. *Ophthalmol Clinics.* 2005;18:41–53.
61. Schmidt MJ, Prabakar RK, Pike S, et al. Simultaneous copy number alteration and single-nucleotide variation analysis in matched aqueous humor and tumor samples in children with retinoblastoma. *Int J Mol Sci.* 2023;24:8606.
62. Le Gall J, Dehainault C, Benoist C, et al. Highly sensitive detection method of retinoblastoma genetic predisposition and biomarkers. *J Mol Diagn.* 2021;23:1714–1721.
63. Orlic M, Spencer CE, Wang L, Gallie BL. Expression analysis of 6p22 genomic gain in retinoblastoma. *Genes Chromosomes Cancer.* 2006;45:72–82.
64. Grasemann C, Grati S, Stephan H, et al. Gains and overexpression identify DEK and E2F3 as targets of chromosome 6p gains in retinoblastoma. *Oncogene.* 2005;24:6441–6449.
65. Ghiam BK, Xu L, Berry JL. Aqueous humor markers in retinoblastoma, a review. *Transl Vis Sci Technol.* 2019;8:13–13.
66. Galardi A, Stathopoulos C, Colletti M, et al. Proteomics of aqueous humor as a source of disease biomarkers in retinoblastoma. *Int J Mol Sci.* 2022;23:13458.
67. Liu W, Luo Y, Dai J, et al. Monitoring retinoblastoma by machine learning of aqueous humor metabolic fingerprinting. *Small Meth.* 2022;6:2101220.
68. Wolf J, Rasmussen DK, Sun YJ, et al. Liquid-biopsy proteomics combined with AI identifies cellular drivers of eye aging and disease in vivo. *Cell.* 2023;186:4868–4884.e4812.
69. Lombard Z, Landouré G. Could Africa be the future for genomics research? *Nature.* 2023;614:30–33.
70. Lumaka A, Carstens N, Devriendt K, et al. Increasing African genomic data generation and sharing to resolve rare and undiagnosed diseases in Africa: a call-to-action by the H3Africa rare diseases working group. *Orphanet J Rare Dis.* 2022;17:230.
71. Peng C-C, Sirivolu S, Pike S, et al. Diagnostic aqueous humor proteome predicts metastatic potential in uveal melanoma. *Int J Mol Sci.* 2023;24:6825.
72. Im DH, Peng C-C, Xu L, et al. Potential of aqueous humor as a liquid biopsy for uveal melanoma. *Int J Mol Sci.* 2022;23:6226.