tvst

Article

Optic Nerve Head Volumetry by Optical Coherence Tomography in Papilledema Related to Idiopathic Intracranial Hypertension

Michelle Dreesbach[1], Lutz Joachimsen[1], Sebastian Küchlin[1], Michael Reich[1], Nikolai J. Gross[1], Alexander U. Brandt[2,3], Florian Schuchardt[4], Andreas Harloff[4], Daniel Böhringer[1], and Wolf A. Lagrèze[1]

[1] Department of Neuroophthalmology, Eye Center, Medical Center, Medical Faculty, University of Freiburg, Germany
[2] NeuroCure Clinical Research Center, Universitätsmedizin, Universität, Berlin, Germany
[3] Department of Neurology, University of California, Irvine, CA, USA
[4] Department of Neurology and Neurophysiology, Medical Center, University of Freiburg, Germany

Correspondence: Wolf A. Lagrèze, Eye Center, Medical Center, 79106 Freiburg, Germany. e-mail: wolf.lagreze@uniklinik-freiburg.de

Received: March 21, 2019
Accepted: November 20, 2019
Published: February 21, 2020

Keywords: papilledema; pseudotumor cerebri syndrome; idiopathic intracranial hypertension; optical coherence tomography; optic nerve head volume

Citation: Dreesbach M, Joachimsen L, Küchlin S, Reich M, Gross NJ, Brandt AU, Schuchardt F, Harloff A, Böhringer D, Lagrèze WA. Optic nerve head volumetry by optical coherence tomography in papilledema related to idiopathic intracranial hypertension. Trans Vis Sci Tech. 2020;9(3):24, https://doi.org/10.1167/tvst.9.3.24

Purpose: Idiopathic intracranial hypertension (IIH) leads to optic nerve head swelling and optic atrophy if left untreated. We wanted to assess an easy to perform volumetric algorithm to detect and quantify papilledema in comparison to retinal nerve fiber layer (RNFL) analysis using optical coherence tomography (OCT).

Methods: Participants with and without IIH underwent visual acuity testing at different contrast levels and static perimetry. Spectralis-OCT measurements comprised standard imaging of the peripapillary RNFL and macular ganglion cell layer (GCL). The optic nerve head volume (ONHV) was determined using the standard segmentation software and the 3.45 mm early treatment diabetic retinopathy study (ETDRS) grid, necessitating manual correction within Bruch membrane opening. Three neuro-ophthalmologists graded fundus images according to the Frisén scale. A mixed linear model (MLM) was used to determine differences between study groups. Sensitivity and specificity was evaluated using the area under the receiver-operating characteristic (ROC).

Results: Twenty-one patients with IIH had an increased ONHV of 6.46 $\pm$ 2.36 mm^3 as compared to 25 controls with 3.20 $\pm$ 0.25 mm^3 ($P < 0.001$). The ONHV cutoff distinguishing IIH from controls was 3.97 mm^3 (i.e. no patient with IIH had an ONHV below and no healthy individual above this value). The area under the curve (AUC) for ONHV was 0.99 and for the RNFL at 3.5 mm 0.90. The Frisén scale grading correlated higher with the ONHV ($r = 0.90$) than with the RNFL thickness ($r = 0.68$). ONHV measurements were highly reproducible in both groups (coefficient of variation <0.01%).

Conclusions: OCT-based volumetry of the optic nerve head discriminates very accurately between individuals with and without IIH. It may serve as a useful adjunct to the rating with the subjective and ordinal Frisén scale.

Translational Relevance: A simple OCT protocol run on the proprietary software of a commercial OCT device can reliably discriminate between normal optic nerve heads or pseudo-papilledema and true papilledema while being highly reproducible. Our normative data and OCT preset may be used in further clinical studies.

Introduction

Papilledema results from increased intracranial pressure and can lead to optic atrophy and visual loss if left untreated.[1,2] An acute rise of intracranial pressure may result from diseases, such as head trauma, cerebral sinus venous thrombosis, or severe stroke. The most common chronic causes, however, are intracranial mass lesions or idiopathic intracranial hypertension (IIH). The incidence of IIH is estimated as 1-3/100,000/year and it usually occurs in young, obese women.[2,3] Its diagnostic criteria are papilledema and a normal neurologic status, except for cranial

Copyright 2020 The Authors

This work is licensed under a Creative Commons Attribution-NonCommercial-NoDerivatives 4.0 International License.

Downloaded from intl.iovs.org on 04/20/2024

nerve palsies, normal brain parenchyma on magnetic resonance imaging, normal cerebrospinal fluid (CSF) composition, and an opening fluid pressure >25 cm H_2O for definite and >20 mm Hg for probable IIH.[4]

In a clinical setting, papilledema is sometimes difficult to differentiate from pseudopapilledema or normal optic nerve heads. Amount and appearance of papilledema are indicative of different levels of intracranial pressure and phases of the underlying disease. Hence, precise and objective noninvasive imaging methods of the optic nerve are needed. Different stages of papilledema have formerly been classified using a grading scheme proposed by Frisén scale.[5] This scale is, however, limited by a high inter- and intrarater variability. The disadvantages of such subjective and noncontinuous methods can be overcome by using optical coherence tomography (OCT). Although mostly associated with macular diseases, its domain has been increasingly broadened to include degenerative optic nerve and visual pathway-related diseases, such as glaucoma, optic neuritis, or multiple sclerosis. Optic nerve head (ONH) swelling, however, is more difficult to assess by OCT and quantification of papilledema has mostly been focused on the peripapillary retinal nerve fiber layer (RNFL).[6,7] However, a volumetric quantification may reflect morphologic changes in the ONH more appropriately.[8–11]

Although previously published studies[8–13] on OCT in papilledema applied automated algorithms relying on individual post hoc software based on Cirrus-OCT (Carl Zeiss Meditec, Oberkochen, Germany) or Spectralis-OCT (Heidelberg Engineering GmbH, Heidelberg, Germany) data, we evaluated an easy to use and straightforward approach available to everybody on a commercial OCT system by using the Spectralis-OCT system. It can be easily used without supplementary software to quantify the ONH volume. In the present study, we compared OCT findings in IIH and controls and tested if they allow for a precise discrimination of patients and healthy controls. In addition, we compared optic nerve head volume (ONHV) to RNFL measurements in the same cohort in order to identify the more reliable measurement parameter.

Methods

Study Population

All individuals were prospectively and consecutively recruited between October 2016 and July 2017. Patients with IIH were recruited from the Departments of Ophthalmology and Neurology, University of Freiburg, Germany. Controls were either volunteers (medical students and hospital staff) or patients with external eye diseases recruited from the emergency eye clinic of the Department of Ophthalmology, University of Freiburg, Germany.

Patients with IIH had to comply with the modified Dandy criteria[4] (symptoms of increased intracranial pressure, being awake and alert, inconspicuous neuroimaging, documented increased intracranial pressure ≥25 mm Hg for definite and ≥20 mm Hg for probable IIH, normal cerebrospinal fluid composition, and no other cause of increased pressure).

Exclusion criteria for both groups comprised an age below 18 years, a spherical equivalent exceeding ±5 D to avoid inference of refraction-related anomalies with the OCT measurements, and any reported previous retinal or optic nerve diseases.

Exclusion criteria for the control group were a perimetric mean defect (MD) worse than −4 dB on static perimetry, a best-corrected visual acuity worse than 20/25, and of note optic disc changes, such as coloboma, macro disc, titled disc, or optic atrophy.

This investigation was performed in compliance with the tenets of the Declaration of Helsinki and was approved by the ethics committee of the Albert-Ludwigs University, Freiburg. Written informed consent was obtained from all subjects after explanation of the nature and possible consequences of the study. Patients and controls were recruited from the Departments of Ophthalmology and Neurology at the Medical Center of the University of Freiburg, Germany.

Neuro-ophthalmogic Examination

Patients and healthy controls underwent the following standarized set of diagnostic procedures. High (100%) and low contrast (2.5%) visual acuity testing was performed with early treatment diabetic retinopathy study (ETDRS) charts. Perimetry was performed with an Octopus-900 perimeter (Haag-Streit, Köniz, Switzerland). A fundus camera (FF450 Plus; Carl Zeiss Meditec VG) was used for optic disc photography to grade papilledema according to the Frisén scale. Reading was independently performed by three experienced neuro-ophthalmologists (W.L., L.J., and N.G.) masked to the subject's affiliation to the patient versus control group. All other diagnostic procedures were performed by technicians naïve to the group assignment and medical history. All patients had undergone a lumbar puncture in their disease history. We used the most recent intracranial pressure reading

Downloaded from intl.iovs.org on 04/20/2024

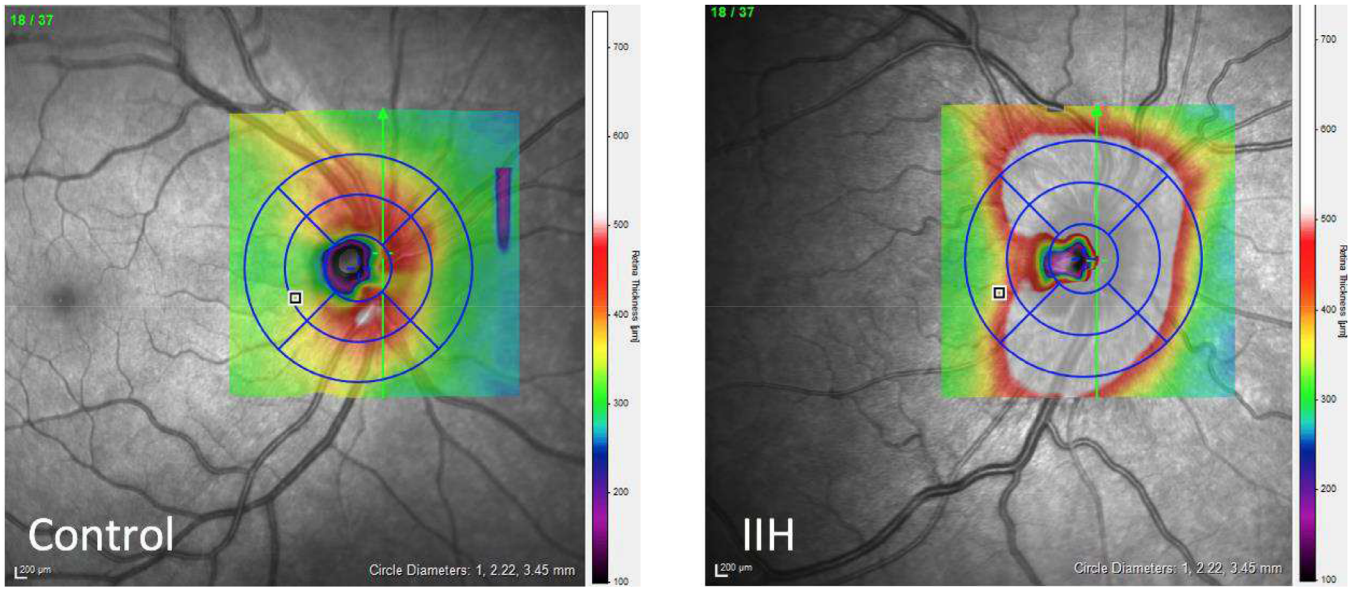

Figure 1. Optical coherence tomography (OCT) imaging of the optic nerve head (ONH). The ONH volume measurement by a custom made preset. A 15° × 15° cube is manually centered onto the ONH and 37 vertical scans are generated. The volume is measured between Bruch's membrane and the inner limiting membrane. The ONH volume is determined by applying the 3.45 mm Early Treatment Diabetic Retinopathy Study (ETDRS) grid.

for our analysis, which was performed in 16 eyes after and 26 eyes before OCT measurements.

For OCT measurements, we applied the Spectralis–OCT (Heidelberg Spectralis spectral domain-optical coherence tomography [SD-OCT], Heidelberg Engineering, Germany) with eye-tracking software (TrueTrack and NSite Axonal Analytics application, version 6.3.4.0). We chose three different presets for image acquisition: (1) The preset *ONH-RC* was used in the standard fashion to measure the peripapillary RNFL-thickness in three circles of 3.5, 4.1, and 4.7 mm diameter around the optic disc. (2) The preset *PPole-N* was applied in the standard fashion, centered on the macula. The ganglion cell layer (GCL) layer was automatically segmented. We determined the GCL layer volume was determined using both the 3.45 mm and a 6 mm ETDRS grid. (3) We custom-defined the preset *ONH-VOL* as scanning the ONH and its surrounding retinal tissue with 37 vertical scans in a 15° × 15° cube, manually centered on the optical nerve head (Fig. 1).

ART was set at 10 B-Scans in high resolution (HR) mode. The ONHV was measured between Bruch's membrane (BM) and the inner limiting membrane (ILM) by superimposing the 3.45 mm ETDRS grid. Both the BM and ILM were delineated automatically by using the Heidelberg Eye Explorer (HEYEX, version 1.9.10.0). Because the BM is interrupted by the lamina cribrosa in the central scans, we manually interpolated the BM within this gap according to the best guess of one operator (i.e. a straight line if the retinal pigment epithelium [RPE] occurred straight next to the lamina cribrosa or a curved line in case of a bent RPE contour; Figs. 2 and 3).

Statistical Analyses

All calculations were performed using the *R platform* (version 3.3.2, Vienna, Austria).[14] Continuous data (e.g. age, CSF opening pressure, and ONHV) are presented as mean ± standard deviation. The correlation of ONHV and RNFL with the study group (healthy vs. IIH) was assessed with a mixed linear model (MLM). We used a random effects model with subject as random effect to test this difference for statistical significance in order to account for the left/right eye correlation. We included age and sex into this model to control for confounding by these covariates as they may potentially differ between cases and controls. We used the NLME package in R. Clinical parameters (Frisén grading) were analyzed accordingly.

Comparisons of means between groups were analyzed via analysis of variance (ANOVA) and Dunnet's contrast. Spearman correlation was used to assess the association between the Frisén grading scale, ONHV, and RNFL thickness. We used the Pearson test to measure the correlation between CSF pressure, ONHV, and RNFL thickness. The predictive power of these parameters was compared by means of receiver operating characteristic (ROC) on the basis of the area

Downloaded from intl.iovs.org on 04/20/2024

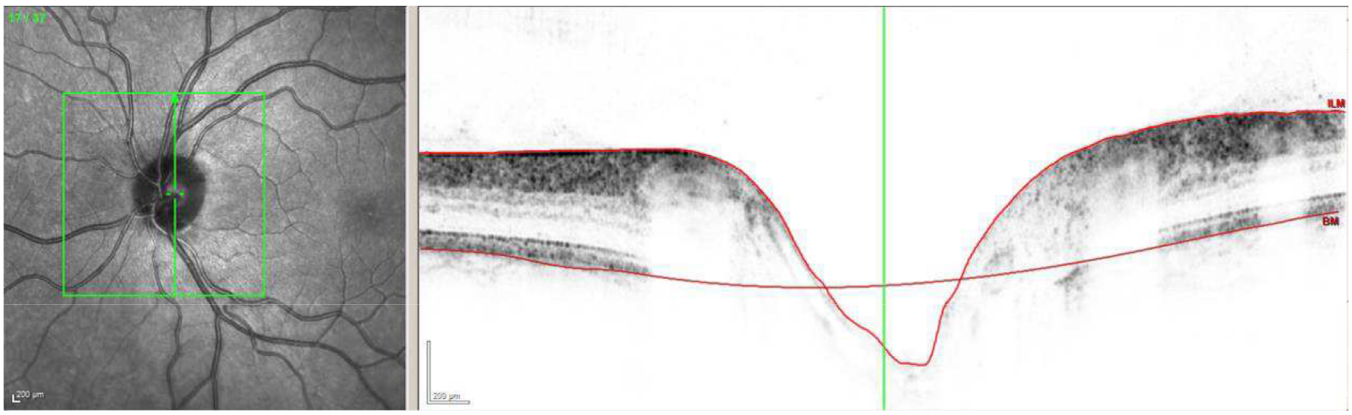

Figure 2. B-Scan of optic nerve head (ONH) volume. The figure shows an ONH B-Scan of a healthy patient, where no manual correction of layer segmentation is needed.

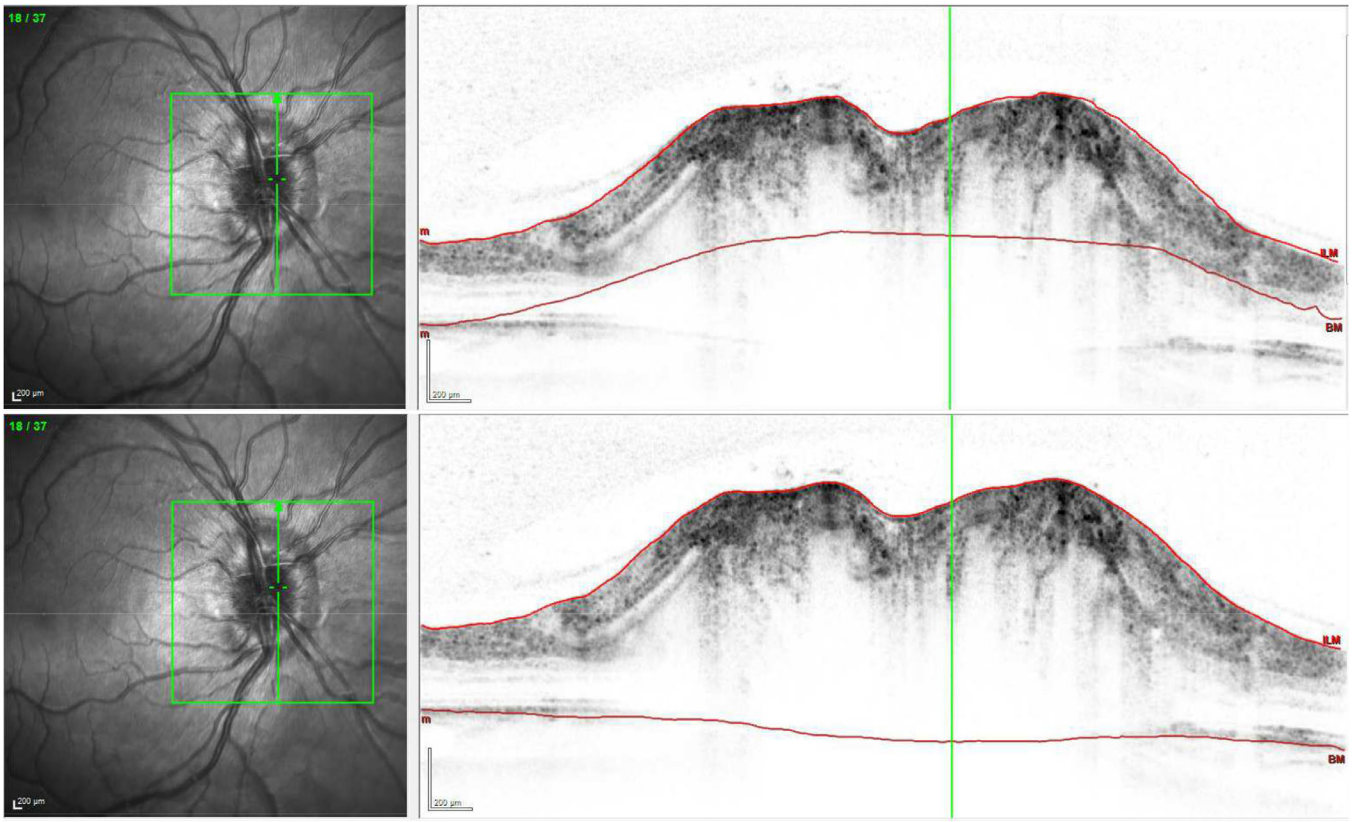

Figure 3. Manual correction of optic nerve head (ONH) scans. Corrections of an exemplary vertical B scan through the ONH showing incorrect layer segmentation of Bruch's membrane by automated segmentation (upper panel) and after manual correction (lower panel).

under the curve (AUC). Optimal cutoff points were selected with the help of Youden's index. To assess intrarater reliability, coefficients of variation were calculated from repeated measurements of the same scans of 10 healthy controls and 10 patients with IIH, the coefficients of variation were calculated. P values < 0.05 were considered statistically significant.

Results

Patient's Characteristics

One hundred forty-three eyes were initially screened, of which 64 eyes were assumed to be normal and 79 suspicious of IIH. Eighteen eyes in the control group

translational vision science & technology

Downloaded from intl.iovs.org on 04/20/2024

Table 1. Functional and Morphometric Baseline Data from Both the Control and IIH Groups

	Control Eyes, n = 46 (Mean ± SD)	IIH Eyes, n = 42 (Mean ± SD)	*P* Value
Age	29.9 ± 10.3	29.9 ± 11.1	0.34
Sex (female)	96%	95%	0.93
HCVA (ETDRS score)	92.4 ± 3	83.7 ± 17.1	<0.01
LCVA (ETDRS score)	64,4 ± 6.1	38.4 ± 20.9	<0.01
MD, dB	1.6 ± 1.1	4.1 ± 5.4	<0.01
Frisén grade	0.2 ± 0.4	2.7 ± 1.5	<0.01
	Control eyes, n = 46 (mean ± SD)	IIH eyes, n = 42 (mean ± SD)	*P* value

ETDRS, early treatment diabetic retinopathy study; HCVA, high-contrast visual acuity; IIH, idiopathic intracranial hypertension; LCVA: low contrast visual acuity; MD, mean defect;.

were excluded for the criteria mentioned in the methods section. We excluded 37 eyes suspicious of IIH subsequently receiving a different diagnosis related to optic disc swelling. As a result, 42 eyes of 21 patients with IIH and 46 eyes of 25 normal healthy controls (both eyes from 21 patients and 1 eye from 4 patients) were included.

The age of the patients with IIH was 30 ± 11 years (mean ± standard deviation) and of the control subjects 30 ± 10 years ($P = 0.34$). Ninety-five percent of patients with IIH and 96% of controls were women ($P = 0.93$). Table 1 summarizes ophthalmologic characteristics of both groups. All patients with IIH underwent at least one lumbar puncture: 13 within 1 week of ocular examination, 5 within the same year, and 3 patients >1 year before (for diagnostic identification). The mean CSF pressure obtained closed to ocular examination was included in the analysis, showing a mean of 35 ± 8.50 cm H_2O (± standard deviation) and a range of 22 mm Hg to 50 mm Hg. Only two patients had a pressure between 20 and 25 mm Hg.

Frisén Grading

In the control group, 35 eyes (76%) were rated grade 0, and 11 eyes were grade 1 (24%). In the IIH group, zero eyes were rated grade 0, 12 eyes were grade 1 (29%), 10 eyes were grade 2 (24%), 4 eyes were grade 3 (10%), 9 eyes were grade 4 (21%), and 7 eyes were grade 5 (17%).

Optic Nerve Head Volume

ONHV quantification was feasible in all participants. In the IIH group, ONHV (6.46 ± 2.36 mm^3) was significantly higher compared with all healthy subjects (3.20 ± 0.25 mm^3, $P < 0.001$). Remarkably, there was almost no overlap between both groups when applying an optimal cutoff at 3.97 mm^3 (Fig. 4), meaning that no patient with IIH had an ONHV below and no healthy individual was above this value.

To assess the intrarater reliability of the manual adaptations of incorrect automatic layer segmentations between ILM and BM, one examiner calculated the ONHV for 10 controls and 10 patients with IIH twice. The coefficient of variation in both groups was very low (<0.01%). A number of scans showed erroneous delineation of BM: of 37 B-Scans, 3 (8%) needed manual corrections in the control group and 11 scans (30%) in the IIH group. The mean error rate of incorrect layer segmentations correlated with the ONHV (r = 0.67, $P < 0.001$). Volumetric analysis and manual control plus correction required 4.2 minutes in the IIH group, compared to only 1.6 minutes in controls.

OCT measurements of ONHV and Frisén grading revealed a strong positive correlation (r = 0.90, $P < 0.001$). MLM analysis showed significant differences of ONHV of all grading levels ($P < 0.001$), except between grades 4 and 5 ($P = 0.57$). An estimated threshold volume of 0.59 mm^3 allowed differentiating clearly between grades 0 and 1 ($P = 0,20$), 1,40 mm^3 between grades 1 and 2, 1.26 mm^3 between grades 2 and 3, 2.14 mm^3 between grades 3 and 4, and 0.66 mm^3 between grades 4 and 5 (Fig. 5).

RNFL Thickness

The mean RNFL thickness in the 3.5 mm peripapillary circle was elevated in patients with IIH (189.30 ± 90.7 µm) when compared to controls (105.71 ± 10.20, $P < 0.001$, Table 2). In contrast to the volumetric ONH data, all RNFL circle diameters showed a certain overlap between both groups (Fig. 6). This finding was most pronounced in the 4.7 mm RNFL circle.

RNFL thickness measurements at 3.5 mm and Frisén grades (Fig. 7) showed a significant positive

translational vision science & technology

Downloaded from intl.iovs.org on 04/20/2024

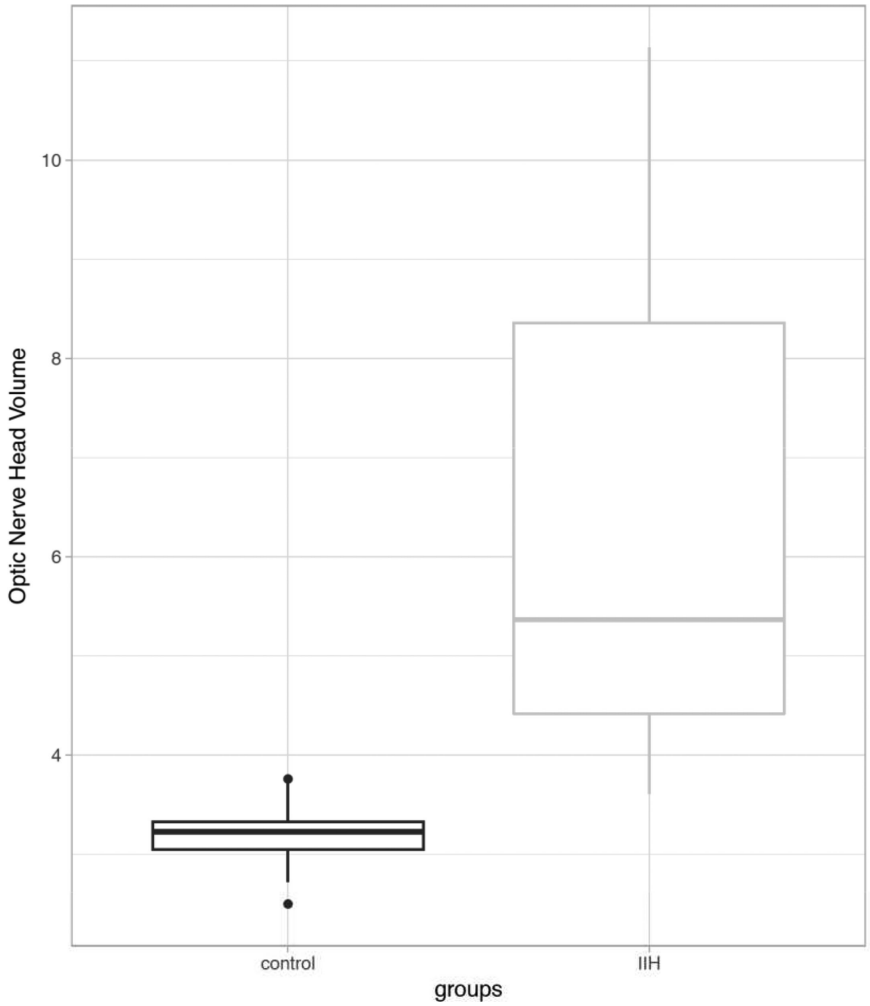

Figure 4. Optic nerve head volume (ONHV) in mm^3. Box plots show the ONHV in both groups. Compared with controls, the ONHV was significantly increased in patients with idiopathic intracranial hypertension (IIH). ONHV allowed to differentiate clearly between patients and controls when using a cutoff of 3.78 mm^3 (horizontal line).

Table 2. Comparison of OCT Data between Controls and Patients with IIH

	Control Eyes, n = 46 (Mean ± SD)	IIH Eyes, n = 42 (Mean ± SD)	MLM
RNFL thickness 3.5, µm	105.7 ± 10.2	189.3 ± 90.7	$P < 0.001$
RNFL thickness 4.1, µm	89.9 ± 7.7	138.9 ± 62.5	$P < 0.001$
RNFL thickness 4.7, µm	78.2 ± 6.8	115.6 ± 52.7	$P < 0.001$
GCL volume 3.45, mm^3	0.47 ± 0.02	0.46 ± 0.06	$P = 0.72$
GCL volume 6.00, mm^3	1.15 ± 0.07	1.12 ± 0.12	$P = 0.83$
ONH volume 3.45, mm^3	3.2 ± 0.25	6.46 ± 2.36	$P < 0.001$

GCL, ganglion cell layer; IIH, idiopathic intracranial hypertension; MLM: mixed linear model analysis; OCT, optical coherence tomography; ONH, optic nerve head; RNFL, retinal nerve fiber layer.

correlation (r = 0.68, $P < 0.001$). In contrast to the ONHV data, MLM analysis did not reveal significant differences of ONHV of all grading levels.

Diagnostic Sensitivity and Specificity

ROC curves of different ONH-related parameters are shown in Figure 8.

translational vision science & technology

Downloaded from intl.iovs.org on 04/20/2024

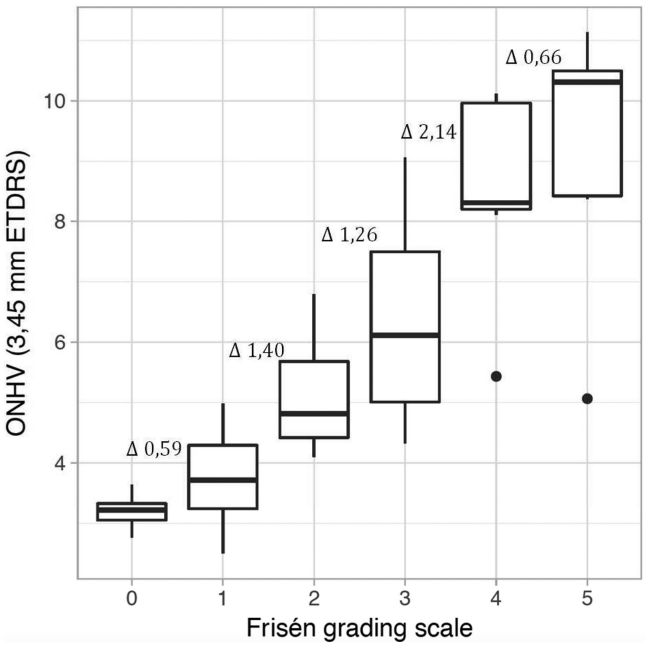

Figure 5. Association between optic nerve head volume (ONHV) and Frisén grade. Boxplots show the mean ONHV of each Frisén grade. Mixed linear model (MLM) showed significant differences in ONHV between grades 0 and 4 ($P < 0.001$). Δ indicating the difference of ONHV mm^3 between two adjacent grades.

The AUC is 0.99 for the ONHV. For the RNFL at 3.5, 4.1, and 4.7 mm, the peripapillary diameter it is 0.90, 0.80, and 0.71, respectively ($P < 0.001$). Optimal cutoff points for the differentiation between patients and controls with highest sensitivity and specificity were: 3.97 mm^3 for ONHV, 108.8 µm RNFL thickness using the 3.5 mm diameter, 90.30 µm RNFL for the 4.1 mm diameter, and 79.71 µm RNFL thickness for the 4.7 mm diameter. The results of Spearman correlation and MLM analysis, which shows significant differentiation between papilledema and healthy optic nerve, were confirmed.

Cerebrospinal Fluid Pressure and Ganglion Cell Layer Volume

Correlations between Frisén grading scale and ONHV (r = 0.90, $P < 0.001$) and also RNFL (r = 0.68, $P < 0.001$) were higher than correlations for CSF opening pressure, which demonstrated a weak positive correlation with both RNFL (r = 0.46, $P = 0.002$) and ONHV (r = 0.58, $P = 0.04$). Macular GCL volume showed no significant difference between both groups (controls: 0.47 ± 0.02; IIH: 0.46 ± 0.06 mm^3 $P = 0.72$) indicating that the patients with IIH were suffering from acute rather than atrophic papilledema. Correlations between macular GCL volume and best-corrected visual acuity (BCVA), low-contrast visual acuity (LCVA), and MD were significant—a little higher using the 6 mm than the 3.45 mm ETDRS grid (6 mm grid: BCVA: r = 0.43, $P < 0.001$; LCVA: r = 0.43, $P < 0.001$; and MD: r = −0.44, $P < 0.001$).

Discussion

Identification of true papilledema plays an important role in clinical decision making. OCT imaging is increasingly used for this purpose. Although most studies applied customized post hoc algorithms requiring specific software, we investigated an easy-to-use OCT algorithm without any additional software that can be applied on any Spectralis-OCT device. We found that it allows for precise discrimination between various grades of papilledema in IIH and optic nerves of healthy controls and can, hence, be used for follow-up assessment of IIH. Our main results are: (1) a cutoff in ONHV of 3.78 mm^3 reliably discriminates between IIH and healthy controls within a 15° × 15° cube, (2) in the ROC analysis, the ONHV was superior to RNFL measurements in this discrimination, (3) the performance of the proprietary segmentation in the Spectralis-OCT worsens with increasing amounts of papilledema, hence requiring more manual correction in advanced papilledema, (4) the intrarater reliability of this manual correction of incorrect automatic layer segmentations between ILM and BM showed only very little and, thus, negligible variation.

SD-OCT has been applied for morphometry of papilledema by others[8–10,12,13] before and, therefore, our approach is not entirely new, yet longitudinal data are sparse as only one study[10] supplied follow-up data. First, Wang et al. applied the Cirrus SD-OCT in 22 patients with a custom-made, automated algorithm.[9] They found their algorithm superior to the commercial preset of the Cirrus device, especially when applying an automated flattening of the RPE contour and its interpolation within the ONH.[15] Its volume correlated significantly with the Frisén scale (r = 0.74), which approximates the results of our approach (r = 0.79). The dimension of the scan field used by this group was 6 × 6 mm as opposed to 4.5 × 4.5 mm in our study. Scott et al. applied the commercially available Cirrus SD-OCT algorithm in a similar cohort of 36 patients with papilledema, correlating the ONH total retinal thickness (TRT) and RNFL with the Frisén scale.[13] They demonstrated high failure rates in OCT segmentations of patients with higher grades of papilledema, however, showing a strong correlation of TRT (r = 0.87) as well as RNFL (r = 0.87) with the Frisén scale. The Nordic Idiopathic

Downloaded from intl.iovs.org on 04/20/2024

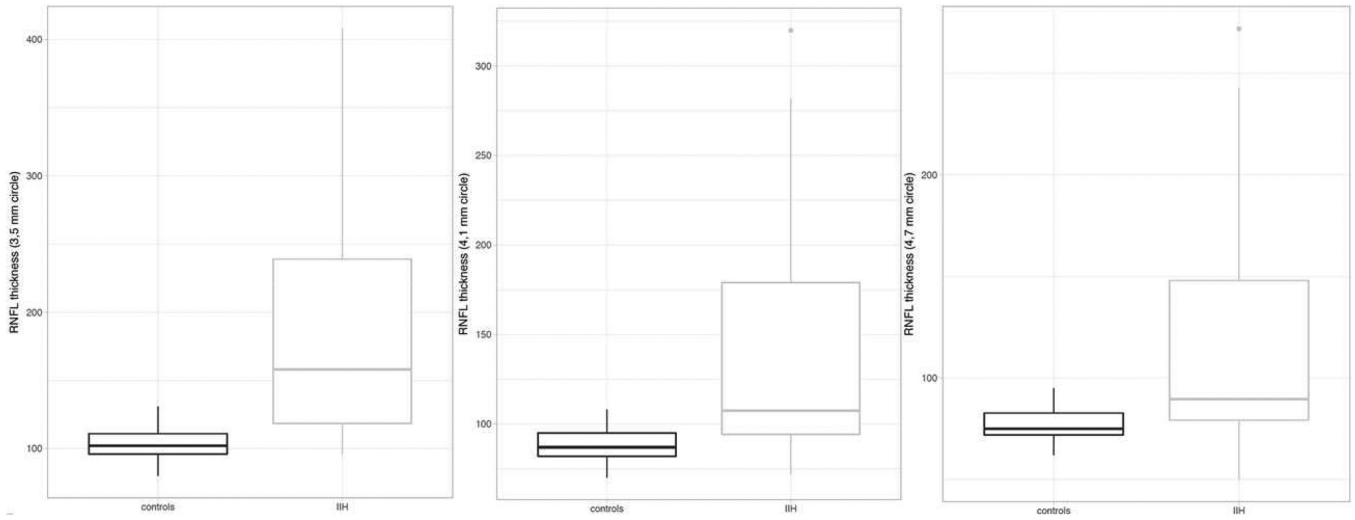

Figure 6. Retinal nerve fiber layer (RNFL) thickness in µm. Box plots of mean RNFL measurements are shown. RNFL thickness was significantly increased in the idiopathic intracranial hypertension (IIH) group, yet did not allow to unequivocally differentiate between both groups because of an overlap of absolute values in both groups, especially in the wider RNFL scan circles.

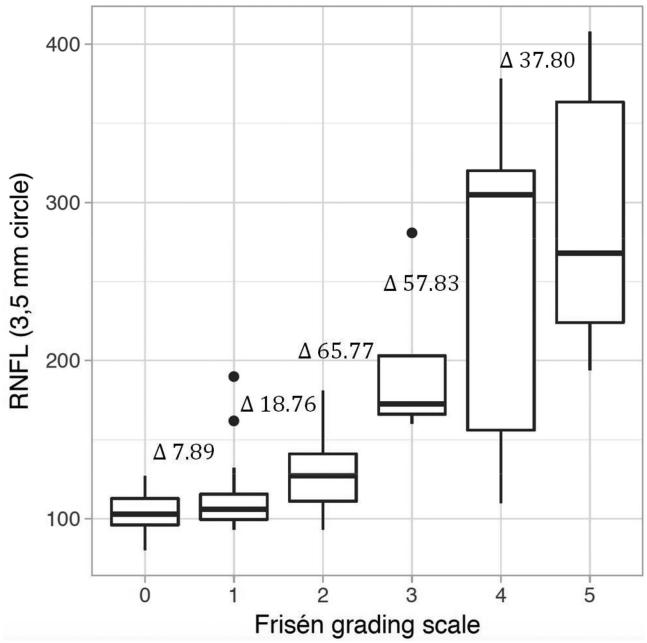

Figure 7. Association between retinal nerve fiber layer (RNFL) thickness and Frisén grade. Boxplots of the mean RNFL thickness of each Frisén grade are presented. RNFL thickness increases with higher Frisén grade, but differences were all not significant. Δ indicating the difference of optic nerve head volume between two Frisén grades.

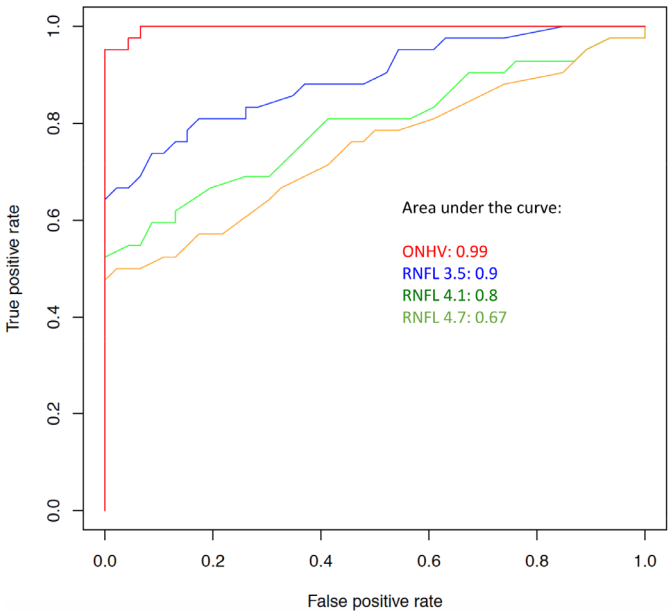

Figure 8. Receiver operating characteristic (ROC) curves. ROC curves for optic nerve head volume (ONHV) and the retinal nerve fiber layer (RNFL) thickness at the three examined diameters surrounding the optic disc are shown, with the estimated volume under the curve. The area under the curve for ONHV (0.99) showed best discrimination among both groups.

Intracranial Hypertension Study Group performed two further trials with Cirrus SD-OCT.[8,12] In part I, 126 patients with IIH with mild visual field loss were included. They applied the same RPE contour flattening algorithm as Garvin et al.[15] In part II, morphometric OCT data were correlated with the Frisén scale and with functional parameters. In contrast to our findings, both the ONHV and RNFL thickness correlated equally well with the Frisén scale and there was no correlation between any OCT parameter and visual function.

translational vision science & technology

Downloaded from intl.iovs.org on 04/20/2024

So far, Spectralis-OCT was only used by two groups[10,11] who applied a custom-made algorithm published by Kadas et al.[16] Kaufhold et al.[11] compared the ONHV in 19 patients (2.30 ± 1.25 mm^3) with a healthy control group (1.08 ± 0.49 mm^3, $P < 0.01$). Albrecht et al.[10] compared 21 patients with papilledema to 27 healthy controls and detected an increased ONHV (5.82 ± 3.71 mm^3 in IIH vs. 2.26 ± 0.58 mm^3 in healthy controls). After initiation of therapy (acetazolamide or weight reduction), they observed a significant decrease of both ONHV and peripapillary RNFL thickness.

Our study differs from the aforementioned ones by the applied device[8,9,12,13] and algorithm.[10,11] Each trial has minor differences, making direct comparisons difficult. Nevertheless, OCT is undoubtedly of high value for the diagnosis of IIH and monitoring of disease progression. The strength of our study is to apply the macular ETDRS, which is easily available to anybody using the commercial Spectralis system. Further, our study is the first to correlate Frisén grades with Spectralis-derived OCT data. ONH OCT differentiates well between healthy patients and patients with IIH and may help discriminating between various stages of papilledema. Such data can be used to identify subjects with diseases of the ONV, such as IIH.

We demonstrated a weak but significant correlation between ONHV and intracranial pressure in our patients with IIH ($r = 0.58$, $P < 0.001$), similar to the findings of Heckman et al.,[17] who performed OCT just before lumbar puncture, and higher than in the Nordic Idiopathic Intracranial Hypertension Study Group[12] ($r = 0.23$). These moderate correlations may be due to the limited size of the cohorts, the time interval between lumbar puncture and measurement of CSF pressure, or delayed morphological adaptation of the optic nerve disc following an increase or decrease of CSF pressure. Thus, larger cohorts need to be studied and OCT should be performed prior to lumbar puncture as well as in fixed intervals after puncture. At present, OCT measurements are able to accurately quantify the extent of changes of the ONH but are not yet able to replace CSF pressure measurements by lumbar puncture for the management of patients with IIH.

Macular GCL thickness did not differ between controls and patients with IIH, indicating that our IIH collective had only little retinal ganglion cell degeneration. It correlated with standard functional clinical parameters, such as BCVA, LCVA, and MD (data not shown), indicating that the macular GCL volume can be used as a measure for optic atrophy, which is difficult to assess in papilledema otherwise.[10,18]

Our investigation has certain limitations: intracranial pressure measurements were not taken simultaneously or close to the OCT measurements. By using proprietary standard OCT software, segmentation errors and layer interpolations had to be corrected by subjective assessment and the corrections depended on best knowledge and judgment of the operator. However, our approach may enable anybody to perform such analyses on a commercial device. The additional time expenditure of about 3 minutes may be a small limiting factor for the transition into clinical routine.

In summary, we have demonstrated that even a simple OCT protocol run on the proprietary software of a commercial OCT device can reliably discriminate between normal optic nerve heads or pseudopapilledema and true papilledema while being highly reproducible. Our normative data and OCT preset may be used in further clinical studies.

Acknowledgments

The authors thank Sebastian Lukas for his invaluable input with regard to the OCT presets and analysis used in this study.

Disclosure: **M. Dreesbach,** None; **L. Joachimsen,** None; **S. Küchlin,** None; **M. Reich,** None; **N.J. Gross,** None; **A.U. Brandt,** None; **F. Schuchardt,** None; **A. Harloff,** None; **D. Böhringer,** None; **W.A. Lagrèze,** None

References

1. Wall M, George D. Idiopathic intracranial hypertension. A prospective study of 50 patients. *Brain J Neurol*. 1991;114:155–180.
2. Markey KA, Mollan SP, Jensen RH, Sinclair AJ. Understanding idiopathic intracranial hypertension: mechanisms, management, and future directions. *Lancet Neurol*. 2016;15:78–91.
3. Raoof N, Sharrack B, Pepper IM, Hickman SJ. The incidence and prevalence of idiopathic intracranial hypertension in Sheffield, UK. *Eur J Neurol*. 2011;18:1266–1268.
4. Friedman DI, Liu GT, Digre KB. Revised diagnostic criteria for the pseudotumor cerebri syndrome in adults and children. *Neurology*. 2013;81:1159–1165.
5. Frisén L. Swelling of the optic nerve head: a staging scheme. *J Neurol Neurosurg Psychiatry*. 1982;45:13–18.

Downloaded from intl.iovs.org on 04/20/2024

6. Savini G, Bellusci C, Carbonelli M, et al. Detection and quantification of retinal nerve fiber layer thickness in optic disc edema using stratus OCT. *Arch Ophthalmol*. 2006;124:1111–1117.
7. Karam EZ, Hedges TR. Optical coherence tomography of the retinal nerve fibre layer in mild papilloedema and pseudopapilloedema. *Br J Ophthalmol*. 2005;89:294–298.
8. OCT Sub-Study Committee for NORDIC Idiopathic Intrqacraqnial Hypertension Study Group,Auinger P, Durbin M, et al. Baseline OCT measurements in the idiopathicIntracranial Hypertension Treatment Trial part I: quality control, comparisons, and variability. *Invest Ophthalmol Vis Sci*. 2014;55:8180–8188.
9. Wang J-K, Kardon RH, Kupersmith MJ, Garvin MK. Automated quantification of volumetric optic disc swelling in papilledema using spectral-domain optical coherence tomography. *Invest Ophthalmol Vis Sci*. 2012;53:4069–4075.
10. Albrecht P, Blasberg C, Ringelstein M, et al. Optical coherence tomography for the diagnosis and monitoring of idiopathic intracranial hypertension. *J Neurol*. 2017;264:1370–1380.
11. Kaufhold F, Kadas EM, Schmidt C, et al. Optic nerve head quantification in idiopathic intracranial hypertension by spectral domain OCT. *PLoS One*. 2017;7:e36965.
12. OCT Sub-Study Committee for NORDIC Idiopathic Intrqacraqnial Hypertension Study Group,Auinger P, Durbin M, et al. Baseline OCT Measurements in the Idiopathic Intracranial Hypertension Treatment Trial, part II: correlations and relationship to clinical features baseline OCT measurements in IIHTT, part II. *Invest Ophthalmol Vis Sci*. 2014;55:8173–8179.
13. Scott CJ, Kardon RH, Lee AG, Frisén L, Wall M. Diagnosis and grading of papilledema in patients with raised intracranial pressure using optical coherence tomography vs clinical expert assessment using a clinical staging scale. *Arch Ophthalmol*. 2010;128:705–711.
14. R Core Team (2017). R: A language and environment for statistical computing. R Foundation for Statistical Computing, Vienna, Austria.
15. Garvin MK, Abramoff MD, Kardon R, et al. Intraretinal layer segmentation of macular optical coherence tomography images using optimal 3-D Graph search. *IEEE Trans Med Imaging*. 2008;27:1495–1505.
16. Kadas EM, Kaufhold F, Schulz C, et al. 3D optic nerve head segmentation in idiopathic intracranial hypertension. In: Tolxdorff T, Desemo TM, Handels H, Meinzer HP, eds. *Bildverarbeitung für die Medizin 2012. Informatik aktuell*. Springer, Berlin, Heidelberg, 2012:262–267.
17. Heckmann JG, Weber M, Jünemann AG, Neundörfer B, Mardin CY. Laser scanning tomography of the optic nerve vs CSF opening pressure in idiopathic intracranial hypertension. *Neurology*. 2004;62:1221–1223.
18. Gu XZ, Tsai JC, Wurdeman A, et al. Pattern of axonal loss in longstanding papilledema due to idiopathic intracranial hypertension. *Curr Eye Res*. 1995;14:173–180.

Downloaded from intl.iovs.org on 04/20/2024