

Biomarkers of Vitreous Cortex Remnants in Eyes With Primary Rhegmatogenous Retinal Detachment

Roberto dell'Omo¹, Marianna Carosielli¹, Giuseppe Rapino¹, Marzia Affatato¹, Pasquale Cucciniello¹, Gianni Virgili², Mariaelena Filippelli¹, Ciro Costagliola³, and Giuseppe Campagna⁴

¹ Department of Medicine and Health Sciences "Vincenzo Tiberio," University of Molise, Campobasso, Italy

² Eye Clinic, AOU Careggi Teaching Hospital, University of Florence, Florence, Italy

³ Department of Ophthalmology, University of Naples "Federico II," Naples, Italy

⁴ Department of Medical-Surgical Sciences and Translational Medicine, University of Rome "Sapienza," Rome, Italy

Correspondence: Roberto dell'Omo, Department of Medicine and Health Sciences "Vincenzo Tiberio," University of Molise, Via Francesco De Sanctis 1, 86100 Campobasso, Italy. e-mail:

roberto.dellomo@unimol.it

Received: March 28, 2023

Accepted: June 2, 2023

Published: June 27, 2023

Keywords: vitreous cortex remnants (VCRs); vitreoschisis; pars plana vitrectomy; optical coherence tomography (OCT)

Citation: dell'Omo R, Carosielli M, Rapino G, Affatato M, Cucciniello P, Virgili G, Filippelli M, Costagliola C, Campagna G. Biomarkers of vitreous cortex remnants in eyes with primary rhegmatogenous retinal detachment. *Transl Vis Sci Technol.* 2023;12(6):24. <https://doi.org/10.1167/tvst.12.6.24>

Purpose: The purpose of this study was to identify pre-operative biomarkers of vitreous cortex remnants (VCRs) in eyes with rhegmatogenous retinal detachment (RRD).

Methods: Prospective case series of 103 eyes treated with pars plana vitrectomy (PPV) to repair RRD. Pre-operatively, optical coherence tomography (OCT) and B-scan ultrasonography (US) were used to study the vitreo-retinal interface and vitreous cortex status. If detected during PPV, VCRs were removed. Images acquired pre-operatively were compared with intra-operative findings and with postoperative OCT images taken at 1, 3, and 6 months of follow-up. Multivariate regression analyses were performed to determine associations between VCRs and pre-operative variables.

Results: The presence of VCRs at the macula (mVCRs) and at the periphery (pVCRs), was ascertained intra-operatively in 57.3% and 53.4% of the eyes, respectively. Pre-operatively, a preretinal hyper-reflective layer (PHL) and a saw-toothed aspect of the retinal surface (SRS) were identified with OCT in 73.8% and 66% of the eyes, respectively. US sections showed a vitreous cortex running close and parallel to the detached retina upon static and kinetic examination (the "lining sign") in 52.4% of the cases. Multivariate regression analyses showed an association between PHL and SRS and intra-operative evidence of mVCRs ($P = 0.003$ and < 0.0001 , respectively) and between SRS and "lining sign" and pVCRs ($P = 0.0006$ and 0.04 , respectively).

Conclusions: PHL and SRS on OCT and the "lining sign" on US appear to be useful pre-operative biomarkers of the intra-operative presence of VCRs.

Translational Relevance: Preoperative identification of VCRs biomarkers may help to plan the operating strategy in eyes with RRD.

Introduction

Progressive, spontaneous separation of the cortical vitreous from the retina is part of the normal aging process.^{1–3} The separation may be complete, implying a detachment of all vitreous material from the surface of the retina, or, more often, neither complete nor uniform. This latter phenomenon, referred to as anomalous posterior vitreous detachment (PVD), is

caused by accelerated vitreous liquefaction without a concomitant weakening of the vitreoretinal adhesion.⁴

Vitreoschisis is a form of anomalous PVD characterized by the posterior vitreous cortex splitting, leaving vitreous cortex remnants (VCRs) adherent to the internal limiting membrane (ILM).^{5,6} The presence of vitreoschisis and associated VCRs have been frequently observed in eyes with vitreo-retinal interface disorders including rhegmatogenous retinal detachment (RRD).^{7–13}

The correct identification of vitreoschisis is critical in pre-operative evaluation and surgical planning because it can have profound impact on surgical approach, prognosis, visual and anatomic outcomes, and risk stratification for subsequent development of proliferative vitreoretinopathy (PVR).

In fact, some authors have proposed that removing VCRs in the eyes with RRD may be beneficial in order to prevent cell proliferation on the retinal surface and avoid epiretinal membrane (ERM) formation and PVR development.^{7,9,12,13} On the other hand, the removal of VCRs is challenging and time-consuming¹⁴ so pre-operative identification of VCRs in the eyes for which pars plana vitrectomy (PPV) and VCRs peeling has been planned to repair RRD would be desirable.

At present no definitive imaging features exist to detect macular or peripheral VCRs.^{15–17}

In this study, we compared images recorded pre-operatively by using optical coherence tomography (OCT) and B-scan ultrasonography (US) with intra-operative findings and postoperative images to possibly identify pre-operative biomarkers of VCRs in patients affected by primary RRDs.

Methods

We conducted a prospective analysis of consecutive patients affected by primary RRD who underwent vitrectomy at the University of Molise, Campobasso, from December 2020 to March 2022. All subjects were treated in accordance with the Declaration of Helsinki. This study was approved by the Institutional Review Board of the University of Molise. Informed consent was obtained from all participants after explanation of the nature and possible consequences of the study.

Pre-operative data collection included a complete medical and ophthalmic history, characteristics of detachment (location, quadrants involved, location and number of retinal breaks, fovea status), lens status, and time from the onset of symptoms suggestive of RRD to surgery. RRD was defined as RRD without PVR (PVR 0) or with PVR grade A or B.¹⁸

Axial length (AXL) measurements were obtained by optical biometry (Lenstar LS 900, Haag-Streit, Köniz, Switzerland) pre-operatively in macula-on RRD and pre- and postoperatively in macula-off RRD. Patients with a history of diabetes, retinal vascular diseases, uveitis, previous vitreoretinal surgery for any cause in the studied or fellow eye, tractional RD, RRD associated with a macular hole, or RRD caused by a giant retinal tear or secondary to trauma were excluded.

OCT Evaluation

Spectral-domain OCT scans were acquired using the Heidelberg Spectralis, version 1.9.13 (Heidelberg Engineering, Heidelberg, Germany). The protocol consisted of a sequence of 97 horizontal sections (B-scan) that covered an area of 55 degrees horizontally and 40 degrees vertically, recorded in the high-resolution mode (1536 A-scan per section) with a distance of 120 μm between individual sections with the “Automatic Real-Time” function incorporated in the software set at 16. Only images with quality ≥ 70 were considered acceptable for analysis.

For the evaluation of the posterior vitreous cortex at the posterior pole on OCT scans (classified as “visible” and “not visible”), eyes were judged as having an acceptable scan position if the top of the scan was at least three “retina thicknesses” above the retinal pigment epithelium at the foveal center in order to capture, if visible, the anterior edge of the premacular bursa, (approximately 708 μm over the retina at the foveal center).¹⁹

Scans for which a good evaluation was not possible because of the substantial height of the macula-off detachment were classified as “not gradable.”

Eyes with a visible premacular bursa of Worst and without visible posterior vitreous cortex were classified as “attached posterior cortex” and excluded from the final analysis. Postoperative OCT images were acquired 1, 3, and 6 months after operation using the “Follow-up” function to detect signs suggestive of ILM peeling (e.g. dissociated optic nerve fiber layer [DONFL]²⁰ and/or temporal macular thinning and other foveal abnormalities) co-occurring with macular (m)VCRs peeling.

US Evaluation

Echographic examinations were performed using Aviso TM (Quantel Medical, Cournon d’Auvergne, France), using a focused probe of 10 Mhz with gain settings set at 105 dB to ensure less wave attenuation and a high signal-to-noise ratio, designed explicitly for vitreous examination. The probe was positioned in transverse (3, 6, 9, and 12 o’clock positions) and longitudinal sections keeping the patient’s eyelids open. For adequate characterization of vitreoretinal relationships, kinetic eye movements were solicited during testing and video recorded in order to capture kinetic properties (movement) of the vitreous body and cortex. Up to 10 seconds of imaging were recorded, and video acquisition was repeated as necessary. For kinetic evaluation, patients were asked to look to the center and back to the examined position (i.e. for transverse

sections at 3, 6, 9, and 12 o'clock) and to hold their gaze until the vitreous appeared to have ceased moving while the probe was held stationary. Kinetic properties were evaluated with B-scan by observing the vitreous cortex motion and its relationships (distance and contour) with the retina before and after eye movement.

The vitreous cortex status anterior to the macula up to the vitreous base was classified as follows: (1) completely detached (with or without collapse of the vitreous cortex)²¹; (2) partially detached; and (3) attached. Eyes with attached vitreous cortex were excluded from the final analysis.

OCT and US Imaging Analysis

Given the current lack of a software capable of detecting automatically the OCT abnormalities described in this study, images analysis was performed manually. Two experienced graders (authors M.C. and M.F.), independently assessed the pre-operative OCT images analyzing each of the 97 B-scans recorded. The same graders, masked to intra-operative findings and timing of follow-up, assessed the postoperative images. Masking between pre-operative and postoperative images was not applicable because retinal detachment was not present in postoperative images. When there was a disagreement between the two graders, a third grader (author C.C.) decided which grader's judgment should be accepted. Two different graders (authors P.C. and G.V.) graders assessed the relationship between the vitreous cortex and retina on each of the US images recorded.

Surgical Technique

All the eyes were managed with 25 or 23G PPV (Constellation Vision System; Alcon, Fort Worth, TX) using a noncontact wide-angle viewing system (Resight Fundus Imaging System; Carl Zeiss Meditec AG, Jena, Germany) by one surgeon (author R.d'O.). Before vitrectomy, phacoemulsification and intraocular lens implantation were performed in all phakic eyes using the same platform.

After the induction of complete vitreous separation (in the presence of a partly detached posterior vitreous cortex) and core/peripheral vitrectomy, 0.5 mL of triamcinolone acetonide (Triesence 40 mg/mL; Alcon Laboratories, Inc., Fort Worth, TX) was injected into the vitreous cavity. Then, the presence of VCRs outside and anterior to the macula, termed peripheral (p)VCRs, was ascertained by scraping the retinal surface with a disposable Nitinol loop (Alcon Grieshaber 25G Finesse Flex Loop; Alcon). In contrast, the presence of mVCRs was evaluated with

a high-magnification contact lens (Alcon Grieshaber DSP Aspheric Macular Lens -59 D; Alcon). If present, mVCRs were removed using either a disposable Nitinol loop or end-gripping forceps (Alcon Grieshaber DSP ILM forceps; Alcon). The entire surgical procedure was video recorded to enable review and judgment upon later analysis.

Statistical Analysis

Continuous variables are described as mean \pm standard deviation (SD) and categorical variables are given by number and percentage or presented as median and interquartile range. Comparisons between the variables studied in relationship to the intra-operative presence of peripheral/macular VCRs were tested with the chi-square test.

Risk factors for mVCRs and pVCRs were assessed through multivariate regression analyses using the generalized linear mixed model with binary distribution and link = logit after adjusting for gender and age. Only the variables with a significance level on chi-square tests were retained for multivariate regression. The results of regressions are expressed as odds ratios (ORs) with 95% confidence intervals (CIs) and *P* values.

Statistical analyses were performed using SAS version 9.4 and JMP PRO version 16 (Institute Inc., Cary, NC). A *P* value < 0.05 was considered statistically significant.

Results

One hundred three eyes from 103 patients (70 men and 33 women) were included in the final analysis. The mean age \pm SD was 64.3 ± 10.1 years (range = 43–88 years).

Pre-Operative Findings

Median (interquartile range) time interval between symptoms suggestive of RRD as reported by the patient and the pre-operative images (US and OCT) was 7 (6–10) days.

Pre-operatively, the retina at the macula was not gradable because of the height of the detachment in eight eyes (7.8%). Seventy-six eyes (73.8%) showed a preretinal hyper-reflective layer (PHL; Figs. 1A, 1B) defined as a fine, discrete line of higher reflectivity adherent to the ILM without signs of wrinkling of the underlying retina and without presence of hyporeflective spaces between the PHL and the ILM. Because we

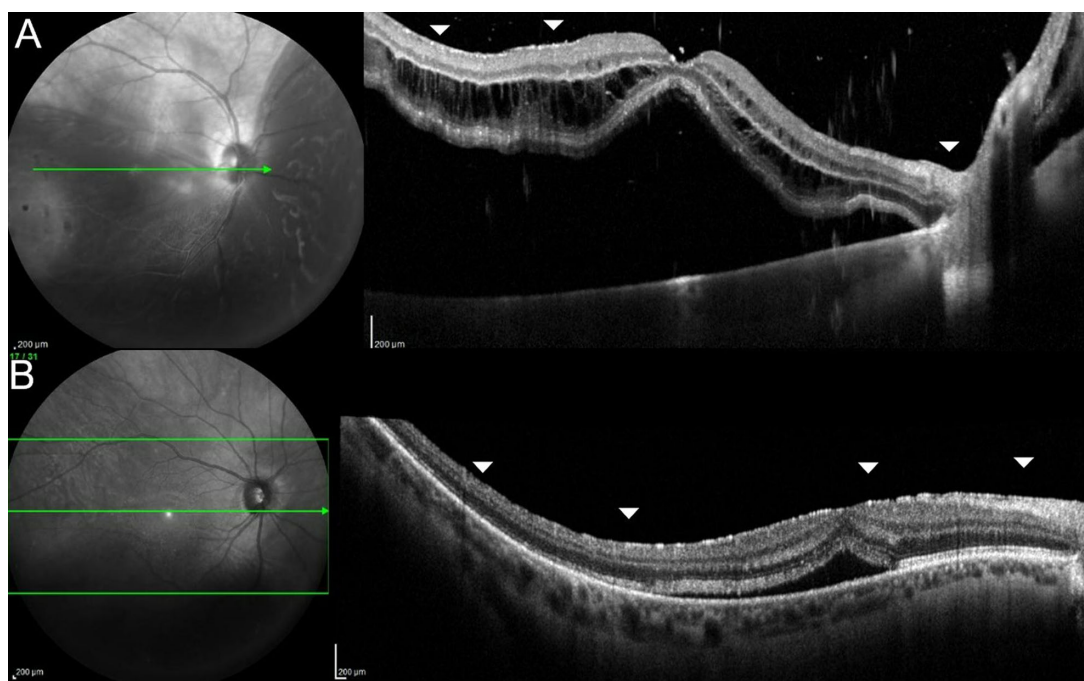


Figure 1. Pre-operative infrared and optical coherence tomography (OCT) images showing a preretinal hyperreflective layer (PHL) on the macula surface in eyes with rhegmatogenous retinal detachment. A PHL limited to some macular areas only (arrowheads), is defined as “focal” (A) whereas a PHL covering the entire macular surface (arrowheads) is defined as “widespread” (B). The bright green line on IR images shows the level of the OCT scans.

hypothesized that this PHL could represent VCRs and because the delineation on OCT between an early stage macular ERM versus alleged mVCRs may be difficult, we decided to refer to it simply as PHL.

The PHL could span the entire length of the scans encompassing the macula (termed “widespread” PHL, observed in 34 cases) or be limited to only some macular areas (termed “focal” PHL, observed in 42 cases). The widespread PHL often extended from the macula to the surface of the optic disc and was identifiable nasally to the disc as well.

Thirteen out of 37 fovea-on cases (35.1%) and 31 out of 66 (46.9%) fovea-off cases showed areas of saw-toothed corrugations of the retinal surface (SRS). These areas were not associated with an overt focal or widespread PHL. The toothing was observed at the border between the attached and detached macula in the fovea-on cases (Figs. 2A–D) and in areas within or anterior to the macula in fovea-off cases (Figs. 2E–H).

In keeping with pre-operative OCT results, US imaging recorded pre-operatively revealed a detached vitreous cortex at the posterior pole in all eyes. US scans imaging the periphery showed a partially detached and a completely detached vitreous cortex in 57 (55.3%) and 46 (44.7%) eyes, respectively. In 54 eyes, the vitreous cortex ran close and parallel to the retina in at least one detached quadrant upon static

and kinetic examination (Figs. 3A, 4D–F, and Supplementary Video). We named this aspect of the vitreous cortex the “lining sign.” Measurements of the distance between the detached vitreous cortex and the retina in the eyes with “lining sign” were manually taken at two points (minimal and maximal distance of the vitreous cortex from the retina) and then averaged. Averaged values ranged from 0.14 to 2.38 mm, thus an arbitrary cut off ≤ 2.50 mm was set to consider the detached cortex “close” to the retina. The detached vitreous cortex was considered as “parallel” to the retina if it showed a contour parallel to the retina surface along the entire length of the retina visible in at least one transversal US scan. The “lining sign” was found in 35 out of 57 eyes (61.4%) with partially detached vitreous (see Figs. 4D, 4F) and in 19 out of 46 eyes (41.3%) with completely detached vitreous but without collapse of the vitreous cortex (Fig. 4E).²¹

Intra-Operative Findings

The presence of VCRs at the macula and outside the macula, up to the vitreous base (defined as mVCRs and pVCRs, respectively), was ascertained intra-operatively and their peeling video-recorded in 59 eyes (57.3%) and in 55 eyes (53.4%), respectively (Figs. 4G–I, Figs. 5A, 5D). The contextual presence

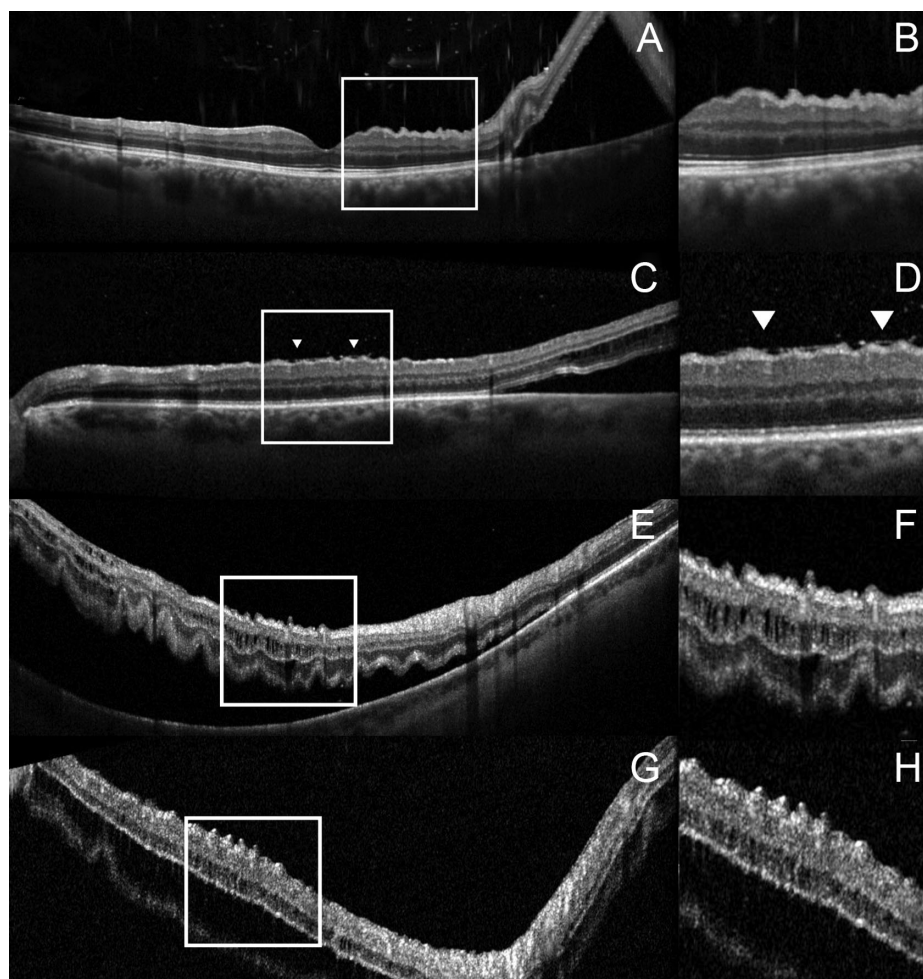


Figure 2. Infrared and optical coherence tomography images of eyes with fovea-on (A-D) and fovea-off (E, H) rhegmatogenous retinal detachment. **A** and **B** A corrugated, saw-toothed aspect of the inner retina, involving the attached retina and starting at the border between the attached and detached macula is visible. **(B, D)** Magnification of the portion of the retina within the squares in **A** and **C**. Note the fine preretinal hyper-reflective layer, presumably vitreous cortex remnants, visible on the macular surface in **D** (arrowheads). **(E, G)** A corrugated, saw-toothed aspect of the inner retina outside the macula. **(F, H)** Magnification of the portion of the retina within the squares in **E** and **G**.

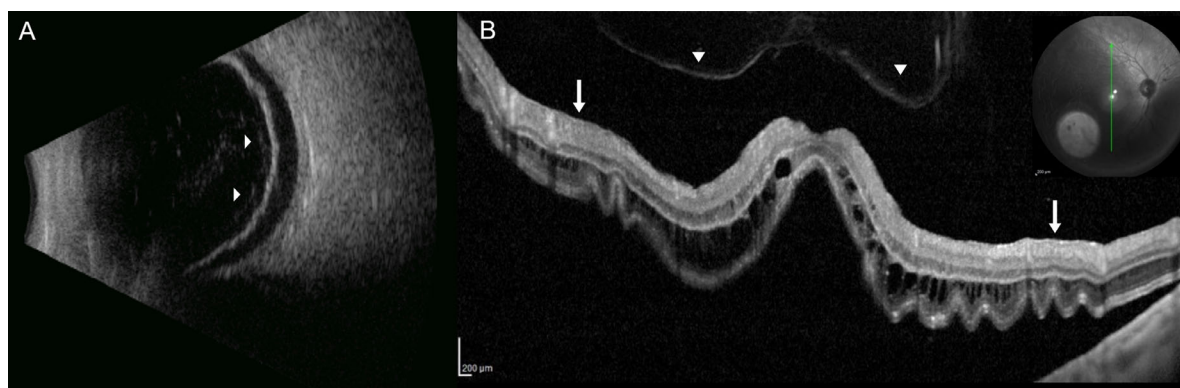


Figure 3. B-scan ultrasonography (US) and optical coherence tomography (OCT) images of an eye with rhegmatogenous retinal detachment and intraoperative evidence of macular and peripheral vitreous cortex remnants. **(A)** The transverse US image of the mid peripheral retina shows a partially detached vitreous cortex (arrowheads) running parallel to the detached retina, the "lining sign." **(B)** The OCT scan shows a detached vitreous cortex (arrowheads) and a preretinal hyper-reflective layer on the inferior and superior aspect of the macula (arrows). The green line on the infrared image shows the level of the OCT scan.

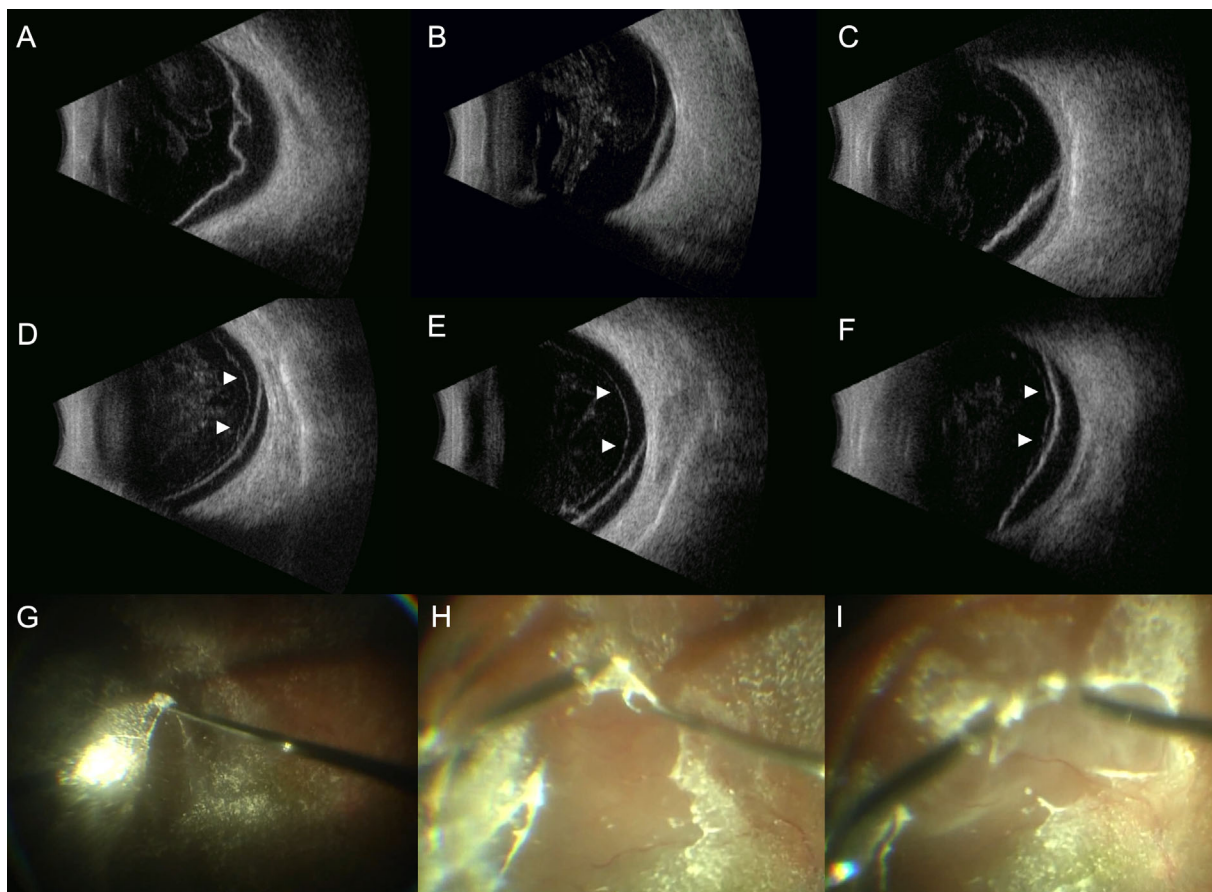


Figure 4. Transverse B-scan ultrasound images that show the relationship between the vitreous cortex and the retina pre-operatively and color pictures showing the corresponding intra-operative findings. (A–C) The vitreous cortex is partially attached **A** and completely detached from the detached retina **B** and **C**, respectively, and appears wavy, not following the contour of the adjacent retina. (D, E, F) Examples of the “lining sign”: the vitreous cortex is partially detached **D** and **F** or completely detached **E** from the retina and runs parallel to the detached and attached retina. (G, H, I) Intra-operative evidence of peripheral vitreous cortex remnants (pVCRs) in the eyes showed in **D**, **E**, and **F** with pre-operative evidence of the “lining sign.” The pVCRs are scraped away from the retinal surface with a flexible nitinol loop and with forceps.

of m- and pVCRs was noted in 47 eyes corresponding to the 79.7% of the eyes in which any VCRs (either macular or peripheral) could be found ($P = 0.009$). Regarding pVCRs, they extended from the macula up to the vitreous base and around retinal breaks, in all cases. Bimanual maneuvers were often necessary to detach them consistently from the retina (Figs. 4H, I) especially in correspondence of the retinal vessels where tight adherences with the retina were found. The relationship between intra-operative presence of VCRs and pre-operative clinical/imaging characteristics are summarized in the Table.

Association Among Pre-Operative, Intra-Operative, and Postoperative Findings

In the univariate analysis, intra-operative evidence of mVCRs was significantly associated with the

presence of PHL (either focal or widespread, $P = 0.009$), widespread PHL ($P = 0.0001$), and SRS ($P = 0.00001$) at the macula. Intra-operative evidence of pVCRs was significantly associated with female sex ($P = 0.003$), SRS anterior to the macula ($P = 0.00007$), and the lining sign on US ($P = 0.0001$). Actually, 43 out of the 55 eyes (78.2%) with intra-operative pVCRs showed the “lining sign” pre-operatively on US scans. Age and lens status were not significantly associated with intra-operative evidence of either mVCRs or pVCRs, whereas there was a nonlinear relationship between AXL and pVCRs (Fig. 6).

Multivariate regression analysis confirmed the associations between widespread PHL (OR = 18.7, 95% CI = 15.9–187.5, $P = 0.003$) SRS at the macula (OR = 25.3, 95% CI = 10.8–126.7, $P < 0.0001$) and intra-operative evidence of mVCRs. However, 25 out of 40 eyes with pre-operative evidence of a PHL and which underwent peeling of mVCRs, still showed

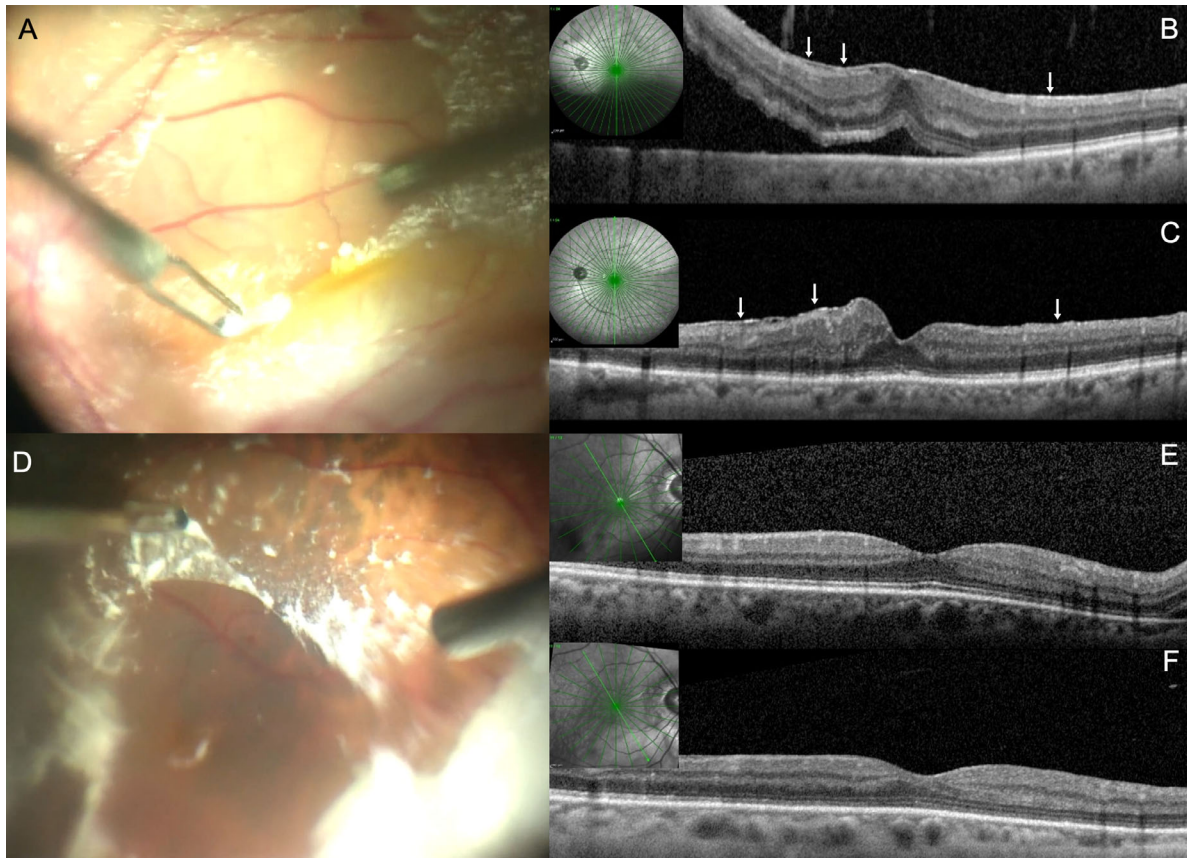


Figure 5. (A, D) Color images showing the intra-operative presence and peeling of macular vitreous cortex remnants (mVCRs) in eyes with rhegmatogenous retinal detachment. (B) Pre-operatively, the optical coherence tomography (OCT) image shows a diffuse preretinal hyper-reflective layer (PHL, arrows) at the macula. (C) One month after operation, despite the intra-operative peeling of mVCRs A, the PHL is still visible on OCT (arrows). (E) Pre-operatively, the OCT image does not reveal an overt PHL on the macular surface. (F) Six months after the operation with peeling of mVCRs, no dissociated optic nerve fiber layer of the retina surface, suggestive of inadvertent inner limiting membrane peeling, is visible. The *bright green lines* on the infrared picture shows the level of the OCT scans.

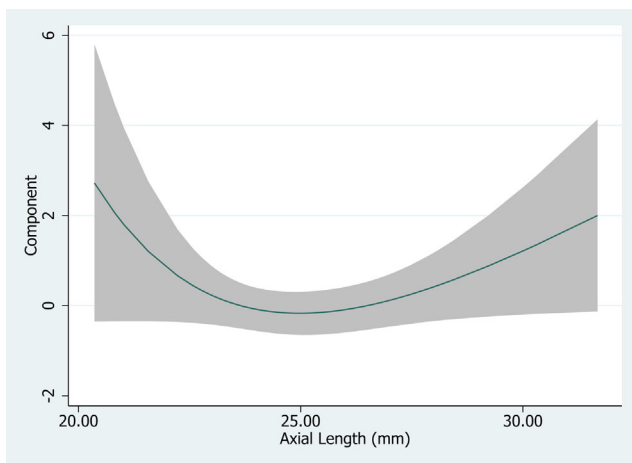


Figure 6. Relationship between the component (fractional polynomial estimated function of axial length) and the linear (raw) axial length variable (millimeters), showing increased probability of peripheral VCR for shorter (hyperopic) or longer (myopic) eyes, compared to emmetropic eyes.

signs of PHL after the operation (Fig. 5C). None of these 25 eyes showed DONFL at any postoperative follow-up. Conversely, DONFL were visible at 3 and 6 month-follow-up visits in 19 eyes in which the peeling of the mVCRs probably resulted in inadvertent concomitant peeling of ILM. In these cases, the PHL at the macula observed pre-operatively was no longer visible postoperatively (Fig. 7B). In one case, mVCRs were found intra-operatively despite the absence of a PHL on pre-operative OCT (Figs. 5E, 5F).

Multivariate regression analysis showed a significant relationship between SRS outside/anterior to the macula (OR = 38.4, 95% CI = 8.9-165.6, $P = 0.0006$) the “lining sign” (OR = 3.97, 95% CI = 1.03-15.33, $P = 0.04$) and pVCRs. Postoperatively, after removal of VCRs, SRS were no longer visible either at the macula or at the periphery in any eye.

Pre-operative presence of “lining sign” and SRS resulted to be sensitive and specific biomarkers for intra-operative detection of pVCRs (81.3% and 74%,

Table. Relationship Between Intra-Operative Presence of Macular and Peripheral Vitreous Cortex Remnants and Pre-Operative Clinical/Imaging Characteristics

Parameter	Absent <i>n</i> (%)	Intra-Operative Peripheral VCRs		Absent <i>n</i> (%)	Intra-Operative Macular VCRs	
		Present <i>n</i> (%)	<i>P</i> Value*		Present <i>n</i> (%)	<i>P</i> Value*
Sex						
Male	40 (83.3)	31 (56.4)	0.003	30 (68.2)	41 (69.5)	0.7
Female	8 (16.7)	24 (43.6)		14 (31.8)	18 (30.5)	
Lens status						
Phakic	27 (56.2)	32 (58.2)	0.84	28 (63.6)	31 (52.5)	0.26
IOL	21 (43.8)	23 (41.2)		16 (36.4)	28 (47.5)	
PVR grade						
0	8 (16.7)	8 (14.5)	0.33	8 (18.2)	8 (13.6)	0.4
A	17 (35.4)	13 (23.6)		15 (34.1)	15 (25.4)	
B	23 (47.9)	34 (61.9)		21 (47.7)	36 (61.0)	
“Lining sign” on B-scan ultrasonography						
No	37 (77.1)	12 (21.8)	0.0001	30 (68.2)	19 (32.2)	0.0003
Yes	11 (22.9)	43 (78.2)		14 (31.8)	40 (67.8)	
Preretinal hyper-reflective layer at the macula on OCT						
No	15 (31.2)	4 (7.3)	0.08	18 (40.9)	1 (1.7)	0.009
Yes	31 (64.6)	45 (81.8)		24 (54.6)	52 (88.1)	
Not gradable	2 (4.2)	6 (10.9)	–	2 (4.5)	6 (10.2)	–
Type of preretinal hyper-reflective layer at the macula on OCT						
Focal	15 (31.2)	27 (49.1)	0.1	22 (50.1)	20 (33.9)	0.0001
Widespread	16 (33.4)	18 (32.7)		2 (4.5)	32 (54.2)	
Saw-toothed appearance of the retinal surface on OCT						
No	46 (79.3)	13 (28.9)	0.0007	47 (87)	12 (20.7)	0.00001
Yes	12 (20.7)	32 (71.1)		8 (13)	46 (79.3)	

Abbreviations: IOL, intraocular lens; OCT, optical coherence tomography; PVR, proliferative vitreoretinopathy.

Values in bold are statistically significant. Comparisons were evaluated using Chi-square test.

and 73.6% and 92.9%, respectively). Conversely, pre-operative PHL showed a very high sensitivity (98.1%) but a low specificity (42.9%) for the intra-operative detection of mVCRs.

Discussion

In this series, pVCRs and mVCRs were found in 53.4% and 57.3% of the studied eyes in line with previous reports.^{9–11,13} In almost 80% of the cases, a contextual presence of m- and pVCRs was noted. A pre-operative widespread PHL and SRS at the macula visualized by OCT were significantly associated with intra-operative evidence of mVCRs, whereas SRS outside/anterior to the macula visualized by OCT and a “lining sign” visualized by US resulted to be

significantly associated with the intra-operative presence of pVCRs.

The term “vitreous cortex remnants” was coined by van Overdam et al.⁹ to indicate the outermost lamellae of the vitreous cortex that, once separated from the inner lamellae because of vitreoschisis, remains attached to the retinal surface. The intra-operative evidence of VCRs in eyes with RRD has been variably reported in the literature: VCRs at the macula have been documented by Kato et al.¹³ in 41.5%, Chen et al.¹⁰ in 43.5%, and Cho et al.⁸ in 75% of the studied eyes. Similarly, VCRs outside the macula up to the equator were reported by van Overdam et al.⁹ in 29% and 44% in 2 different series, by Assi et al.¹¹ in 42% and by Rizzo et al.¹² in 80.6% of the cases. However, none of these studies focused on the pre-operative vitreous cortex status that was often defined only based on ophthalmoscopy and rarely analyzed using OCT or US.

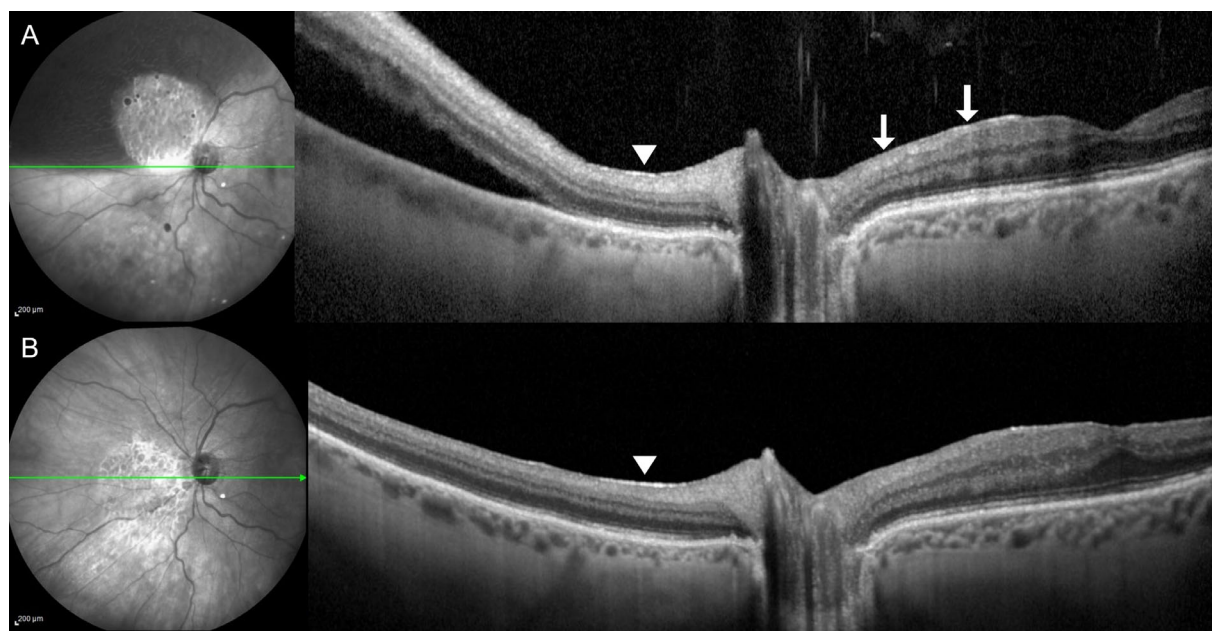


Figure 7. Infrared (IR) and optical coherence tomography (OCT) images showing the pre-operative presence of a preretinal hyper-reflective layer (PHL) on the nasal aspect of the macula (*arrows*) and nasally to the optic disc (*arrowhead*) in an eye with supero-nasal rhegmatogenous retinal detachment (**A**). One month after pars plana vitrectomy and peeling of the vitreous cortex remnants (VCRs) at the macula, the PHL on the nasal aspect of the macula is no longer visible and the retina surface appears smooth. VCRs were not removed nasally to the optic disc where the PHL is still visible (*arrowhead*, **B**). The *green lines* on the IR pictures show the level of OCT scans.

In this study, we investigated whether pre-operative imaging, specifically spectral-domain OCT and US, could provide reliable information about the presence of intraoperative VCRs in eyes with RRD in order to better plan, pre-operatively, the surgical strategy and the operating time for those eyes undergoing PPV.

OCT imaging was used to study the vitreo-retinal interface at the posterior pole, whereas US imaging was used to study the relationship between the vitreous cortex and the retina at the mid-far periphery because OCT has a limited, narrow range of observation in eyes with RRD and is inadequate for examining real-time vitreous movement.^{15,16}

On US imaging, 52.4% of the eyes examined showed a detached vitreous cortex not collapsed but running parallel to the detached retina surface, both on static and kinetic examination. We called this aspect of the vitreous cortex the “lining sign.” There were 78.2% of the eyes with “lining sign” that showed intra-operative evidence of pVCRs and multivariate regression analysis confirmed that the pre-operative presence of the “lining sign” on US scans carries a four-fold higher risk of finding pVCRs intra-operatively. The sensitivity and specificity of the “lining sign” on US for detecting intra-operatively pVCRs were 81.3% and 74%, respectively. Why the eyes with the lining sign on US scans show pVCRs intra-operatively is not clear. We can

hypothesize that some connections remains between the split outer VCRs and inner parts of the detached posterior vitreous cortex but these connections are probably too subtle to be appreciated by ophthalmoscopy or US.^{22,23} Presumably, by virtue of these connections, the split inner portion of the vitreous cortex remains close and parallel to the VCRs lying on the retinal surface.

Another variable significantly associated with the intra-operative evidence of VCRs (at the macula and in the periphery) was the SRS. These high-frequency corrugations of the retinal surface were generally not associated with any overt PHL, although in some eyes a very fine and discontinuous hyper-reflective layer on the retinal surface was visible concomitantly with SRS. It is possible that VCRs confer stiffness to the retinal surface and such stiffness may cause the formation of SRS on a redundant, detached retina. Depending on the thickness and grade of adherence of the VCRs to the underlying retina, the SRS would be randomly distributed in the context of the detached retina. However, in fovea-on cases, we consistently observed SRS at the border of the detachment. This is probably due to the effect of the tractional forces exerted by the VCRs on the inner retina that could be more evident in the areas of transition between attached and detached retina because, in an attached

retina, the outer retina is normally stiffer than the inner retina.²⁴

The pre-operative evidence of SRS on OCT images resulted to be reasonably sensitive (73.6%) and highly specific for the intra-operative detection of VCRs (92.9%).

Regarding PHL, 86.4% of the eyes with pre-operative PHL (either focal or widespread) showed intra-operative evidence of mVCRs. The presence of PHL on pre-operative OCT resulted to be highly sensitive (98.1%) but poorly specific (42.9%) for the intra-operative detection of mVCRs. Multivariate analysis only confirmed a significant association between widespread PHL and mVCRs and postoperative OCT imaging showed residual traces of PHL in 25 out of 40 eyes that had undergone mVCR peeling. It is possible that what is appreciated on OCT as PHL is made of several layers, and during the operation we successfully removed only the most superficial (what appeared intra-operatively as mVCRs) leaving behind the outermost layer. Among the outermost layers, there could also be the ILM in cases in which strong adhesions exist between VCRs and ILM. Actually, Cho et al.⁸ reported a 30% incidence of postoperative ERM during a follow-up period of at least 6 months in eyes with RRD that had undergone PPV and scraping of the VCRs at the macula. This figure contrasts with the incidence of postoperative ERM after ILM peeling during PPV for RRD that has been reported to range between 0% and 9% in a follow-up period of 6 to 12 months^{25–27} and suggest that, although the surgeon may have the impression of thoroughly scraping away VCRs from the macula during the operation, some residual may be inadvertently left on the retinal surface and promoted subsequent membranes growth. Interestingly, a landmark histopathologic study on preretinal membranes,²⁸ revealed that in eyes with vitreous detachment and with residual macular “cortical vitreous membranes,” those membranes are often multilaminated and comprised of alternating layers of glial cells and cortical vitreous. More recently, a histopathological analysis of surgical specimens harvested from eyes with primary RRD identified different compositions of VCRs/membranes in terms of collagen and cells that were attributed to different stages in the PVR formation.²⁹ Thus, it is possible that, depending on a specific histological composition of VCRs, their removal may result more difficult and incomplete in some cases. As a consequence, if a correspondence really exists between PHL and VCRs, we expect to find in some eyes postoperative PHL persistency despite an apparently successful intra-operative VCRs removal. In these eyes, only the peeling of ILM could guarantee

a complete VCR removal. Indeed, we observed that in no case in which the ILM was inadvertently peeled off along with VCRs, the PHL was still visible after the operation. Alternatively, it is possible that, according to a model previously theorized for the pathogenesis of macular pucker,⁴ the scraping/peeling maneuvers to remove VCRs create microbreaks in the ILM through which glial cells may migrate and proliferate giving rise to the PHL. However, this hypothesis seems to be unlikely, because PHL was visible since the first month after the operation.

Previous studies have proposed that myopia and older age may be risk factors for the presence of VCRs.^{11,12,30,31} The results of the current study support in part these relationships because a nonlinear association between AXL and VCRs was observed: in our sample, a trend between increasing AXL and increasing rate of VCRs was noted for AXL >25 mm. Conversely, no significant associations were found among VCRs and age, lens status, and grade of PVR.

An interesting finding of this study was the association, in univariate analysis, between female sex and intra-operative presence of pVCR. Reduced hyaluronic acid synthesis associated with declining estrogen levels in postmenopausal women may promote vitreous liquefaction and possibly explain the higher incidence of vitreoschisis and thus VCRs in women.^{32,33}

This study has some limitations. The presence of VCRs was not determined objectively or masked, and the number of patients recruited was relatively small. Furthermore, the evaluation of the “lining sign” was somewhat qualitative. However, to the best of our knowledge, this study is the first attempt to evaluate if imaging may provide clues for the presence of intra-operative VCRs. Another strength is the prospective design of this study and the fact that all the eyes were operated on by a single surgeon, this limiting the chance that identification of VCRs was influenced by different surgical skills.

In conclusion, VCRs can be found at the macula and peripheral retina in more than 50% of eyes with primary RRD. Both a PHL and SRS evaluated by OCT and the “lining sign” evaluated by US appear to be valid pre-operative biomarkers of intra-operative presence of VCRs. Thus, in patients with pre-operative echographic and/or OCT evidence of VCRs, the surgeon should be particularly vigilant in verifying the complete removal of the posterior hyaloid during PPV.

Further larger studies are needed to confirm our preliminary results.

Acknowledgments

Disclosure: **R. dell’Omo**, None; **M. Carosielli**, None; **G. Rapino**, None; **M. Affatato**, None; **P. Cucciniello**, None; **G. Virgili**, None; **M. Filippelli**, None; **C. Costagliola**, None; **G. Campagna**, None

References

- Schepens CL. *The vitreous and vitreoretinal interface*. New York, NY: Springer-Verlag; 1987:25–32.
- Sebag J. Age-related changes in human vitreous structure. *Graefes Arch Clin Exp Ophthalmol*. 1987;225(2):89–93.
- Tsukahara M, Mori K, Gehlbach PL, Mori K. Posterior vitreous detachment as observed by wide-angle OCT imaging. *Ophthalmology*. 2018;125(9):1372–1383.
- Sebag J. Anomalous posterior vitreous detachment: a unifying concept in vitreo-retinal disease. *Graefes Arch Clin Exp Ophthalmol*. 2004;242(8):690–698.
- Sebag J. Vitreoschisis. *Graefes Arch Clin Exp Ophthalmol*. 2008;246(3):329–332.
- Kishi S, Demaria C, Shimizu K. Vitreous cortex remnants at the fovea after spontaneous vitreous detachment. *Int Ophthalmol*. 1986;9(4):253–260.
- Sonoda KH, Sakamoto T, Enaida H, et al. Residual vitreous cortex after surgical posterior vitreous separation visualized by intravitreal triamcinolone acetonide. *Ophthalmology*. 2004;111(2):226–230.
- Cho EH, Ku HC, Il W, Lee EK. Residual vitreous cortex at the fovea during vitrectomy for primary rhegmatogenous retinal detachment repair. *Retina*. 2018;38(8):1549–1555.
- van Overdam K. Vitreoschisis-induced vitreous cortex remnants: missing link in proliferative vitreoretinopathy. *Acta Ophthalmol*. 2020;98(2):e261–e262.
- Chen TY, Yang CM, Liu KR. Intravitreal triamcinolone staining observation of residual undetached cortical vitreous after posterior vitreous detachment. *Eye (Lond)*. 2006;20(4):423–427.
- Assi A, Khoueir Z. Prevalence of vitreous cortex remnants in eyes with primary rhegmatogenous retinal detachment undergoing vitrectomy. *Retina*. 2021;41(7):1403–1406.
- Rizzo S, de Angelis L, Barca F, et al. Vitreoschisis and retinal detachment: new insight in proliferative vitreoretinopathy. *Eur J Ophthalmol*. 2022;32(5):2833–2839.
- Kato Y, Inoue M, Hirakata A. Effect of foveal vitreous cortex removal to prevent epiretinal membrane after vitrectomy for rhegmatogenous retinal detachment. *Ophthalmol Retina*. 2021;5(5):420–428.
- Charteris DG. Proliferative vitreoretinopathy: revised concepts of pathogenesis and adjunctive treatment. *Eye (Lond)*. 2020;34(2):241–245.
- Rezende FA, Kapusta MA, Burnier MN, et al. Preoperative B-scan ultrasonography of the vitreoretinal interface in phakic patients undergoing rhegmatogenous retinal detachment repair and its prognostic significance. *Graefes Arch Clin Exp Ophthalmol*. 2007;245(9):1295–1301.
- Kičová N, Bertelmann T, Irle S, et al. Evaluation of a posterior vitreous detachment: a comparison of biomicroscopy, B-scan ultrasonography and optical coherence tomography to surgical findings with chromodissection. *Acta Ophthalmol*. 2012;90(4):e264–e268.
- Sebag J. Vitreoschisis in diabetic macular edema. *Invest Ophthalmol Vis Sci*. 2011;52(11):8455–8456.
- Machemer R, Aaberg TM, Freeman HM, et al. An updated classification of retinal detachment with proliferative vitreoretinopathy. *Am J Ophthalmol*. 1991;112(2):159–165.
- Itakura H, Kishi S. Evolution of vitreomacular detachment in healthy subjects. *JAMA Ophthalmol*. 2013;131(10):1348–1352.
- Tadayoni R, Paques M, Massin P, et al. Dissociated optic nerve fiber layer appearance of the fundus after idiopathic epiretinal membrane removal. *Ophthalmology*. 2001;108(12):2279–2283.
- Ota A, Tanaka Y, Toyoda F, et al. Relationship between variations in posterior vitreous detachment and visual prognosis in idiopathic epiretinal membranes. *Clin Ophthalmol*. 2015;21(10):7–11.
- Sebag J. Imaging vitreous. *Eye (Lond)*. 2002;16(4):429–439.
- Itakura H, Kishi S, Li D, Akiyama H. Observation of posterior precortical vitreous pocket using swept-source optical coherence tomography. *Invest Ophthalmol Vis Sci*. 2013;54(5):3102–3107.
- Qu Y, He Y, Zhang Y, et al. Quantified elasticity mapping of retinal layers using synchronized acoustic radiation force optical coherence elastography. *Biomed Opt Express*. 2018;9(9):4054–4063.
- Nam KY, Kim JY. Effect of internal limiting membrane peeling on the development of epiretinal membrane after pars plana vitrectomy for pri-

- mary rhegmatogenous retinal detachment. *Retina*. 2015;35(5):880–885.
26. Akiyama K, Fujinami K, Watanabe K, et al. Internal limiting membrane peeling to prevent post-vitrectomy epiretinal membrane development in retinal detachment. *Am J Ophthalmol*. 2016;171:1–10.
 27. Forlini M, Date P, Ferrari LM, et al. Comparative analysis of retinal reattachment surgery with or without internal limiting membrane peeling to prevent postoperative macular pucker. *Retina*. 2018;38(9):1770–1776.
 28. Clarkson JG, Green WR, Massof D. A histopathologic review of 168 cases of preretinal membrane. *Am J Ophthalmol*. 1977;84(1):1–17.
 29. van Overdam KA, van den Bosch TPP, van Etten PG, Uppal GS, Veckeneer M, Verdijk RM. Novel insights into the pathophysiology of proliferative vitreoretinopathy: the role of vitreoschisis-induced vitreous cortex remnants. *Acta Ophthalmol*. 2022;100(8):e1749–e1759.
 30. Yonemoto J, Ideta H, Sasaki K, et al. The age of onset of posterior vitreous detachment. *Graefes Arch Clin Exp Ophthalmol*. 1994;232(2):67–70.
 31. Sebag J. *The vitreous: structure, function, and pathobiology*. New York, NY: Springer-Verlag; 1989:80–95.
 32. dell’Omo R, De Turre S, Costagliola C, et al. Foveal abnormality associated with epiretinal tissue of medium reflectivity and Increased blue-light fundus autofluorescence signal (FATIAS). *Graefes Arch Clin Exp Ophthalmol*. 2019;257(12):2601–2612.
 33. Larsson L, Osterlin S. Posterior vitreous detachment. A combined clinical and physiochemical study. *Graefes Arch Clin Exp Ophthalmol*. 1985;223(2):92–95.

Supplementary Material

Supplementary Video S1. B-scan ultrasonography video showing the “lining sign” on a transversal scan: the vitreous cortex runs close and parallel to the retina upon static and kinetic examination. For kinetic evaluation, patients are asked to look to the center and back to the examined position and to hold their gaze until the vitreous appears to have ceased moving while the probe is held stationary. Kinetic properties are evaluated with B-scan by observing the vitreous cortex motion and its relationships (distance and contour) with the retina before and after eye movement. An arbitrary distance ≤ 2.50 mm between the vitreous cortex and the retina was set to consider the detached cortex “close” to the retina. The detached vitreous cortex was considered as “parallel” to the retina if it showed a contour parallel to the retina surface along the entire length of the retina visible in at least one transversal ultrasonography scan.