

OCTA Signal Quality Augmentation Using the Isometric Handgrip Test to Maximize Vascular Flow (SQUEEZE): A Randomized Crossover Trial

Matt Trinh¹, Judy Nam¹, Meenakshi Kumar¹, and Lisa Nivison-Smith¹

¹ School of Optometry and Vision Science, University of New South Wales, Sydney, Australia

Correspondence:

Lisa Nivison-Smith, School of Optometry and Vision Science, UNSW Sydney, NSW 2052, Australia. e-mail: l.nivison-smith@unsw.edu.au

Received: November 14, 2023

Accepted: February 7, 2024

Published: March 26, 2024

Keywords: optical coherence tomography angiography; signal quality; isometric handgrip test; vascular flow; sympathomimetic; pressor

Citation: Trinh M, Nam J, Kumar M, Nivison-Smith L. OCTA signal quality augmentation using the isometric handgrip test to maximize vascular flow (SQUEEZE): A randomized crossover trial. *Transl Vis Sci Technol.* 2024;13(3):22, <https://doi.org/10.1167/tvst.13.3.22>

Purpose: To determine if performing the isometric handgrip test (IHGT) can augment optical coherence tomography angiography (OCTA) vascular signal quality in eyes with macular abnormalities.

Methods: A randomized, single-blinded crossover trial was conducted including 36 participants with macular abnormalities, randomized to undergo OCTA with or without the IHGT, then crossed over to the alternate “intervention” after 1 minute. The primary outcome was OCTA signal quality after 1 minute of squeezing at 50% maximum grip strength. Secondary outcomes were other measures of vascular flow and systemic blood pressure (BP), also regressed against person- and eye-level covariables.

Results: Primary analysis of OCTA signal quality with versus without the IHGT was nonsignificant ($P = 0.73$). Nested analyses showed that the IHGT resulted in increased OCTA B-scan retinal vascular flow signal (2.95 [−1.64 to 7.55] $\Delta\%$, $P < 0.05$) and increased systolic BP, diastolic BP, pulse pressure, and mean arterial pressure (4.94 [0.41 to 9.47] to 12.38 [8.01 to 16.75] mm Hg, $P < 0.05$). OCTA signal quality and en face vessel density and perfusion changes were associated with sex, refraction, race/ethnicity, and right-hand IHGT use ($P < 0.05$). Greater increases in systolic and diastolic BP and mean arterial pressure were generally associated with right-hand IHGT use and greater maximum grip strength ($P < 0.09$).

Conclusions: The IHGT can temporarily increase OCTA B-scan retinal vascular flow signal in participants with macular abnormalities. IHGT-induced changes to systemic BP appear to be linked to absolute (rather than relative) grip strength, implying that the IHGT may be ineffective with low grip strength. Further research in larger populations is warranted.

Translational Relevance: This study provides early validation that the IHGT may augment OCTA output, which may lead to improved noninvasive detection of pathologic vascular changes.

Introduction

Optical coherence tomography angiography (OCTA) enables imaging of the retinal and choroidal vasculature that is noninvasive and cost-efficient relative to the current gold standard—intravenous angiography.^{1,2} Use of OCTA, however, has been partly limited³ by sporadic quality of output images, particularly in older, diseased eyes.^{4–6} For example, lower OCTA signal quality is associated with reduced magnitude and poorer repeatability of measurements,⁷

which may result in inconsistent interpretations of patients’ retinal–choroidal vascular integrity.^{4–6}

Augmenting vascular signal quality could improve the validity of using OCTA as an alternate, accessible imaging modality for assessing the retinal–choroidal vasculature. This could be achieved using an in-office exercise such as the isometric handgrip test (IHGT), which induces a sympathomimetic response,^{8,9} temporarily elevating systemic blood pressure (BP). Results demonstrating the potential effects of the IHGT on the retina and/or choroid, however, are still limited. A recent study has suggested

that the IHGT may actually decrease retinal vascular flow signal in normal and diseased eyes,^{10,11} possibly due to local vasoconstriction.^{12,13} Alternatively, other studies have reported that performing the IHGT can result in increased visualization of the retinal and choroidal^{14,15} vasculature in eyes with normal health and central serous chorioretinopathy.^{16–19} For the latter,¹⁸ the IHGT was reported to improve detection of choroidal neovascularization on OCTA imaging via improved visualization of the pathologically disrupted choroidal vasculature.^{20–23}

Broader application of this technique in other diseases affecting the macular vascular architecture has not yet been explored. Similarly, the potential impact of other factors, such as participant demographics, the presence of cardiovascular disease, caffeine/alcohol/cigarette intake, time since waking, and hand laterality, on the sympathomimetic response have not yet been well controlled for in previous studies. Thus, this prospective, randomized crossover pilot trial explores whether performing the IHGT with OCTA can augment vascular flow signal in participants with various abnormalities that affect the macular vasculature. We employ a strict crossover study design, accounting for potential operator bias²⁴ and period effects (i.e., time-of-intervention effects such as dry eyes²⁵ or learning effects after successive scans) to ascertain the utility of IHGT with OCTA.

Methods

This study was a single-center, prospective, randomized, masked, crossover pilot trial, registered prospectively in the Australian New Zealand Clinical Trials Registry (ACTRN12621001522808, without amendment) on November 9, 2021, and following the Consolidated Standards of Reporting Trials (CONSORT) guidelines.²⁶ A crossover design was selected rather than a traditional parallel-group design due to the reduced variability of within-participant versus between-participant comparisons.²⁷

Included participants represented a convenience, indiscriminate sample of patients (18 years or older) referred to the Centre for Eye Health (CFEH), Sydney, Australia from April 7, 2022, to August 18, 2022, for comprehensive assessment of various macular abnormalities, including but not limited to vitreomacular tractional disease, age-related macular degeneration, and macular dystrophies. CFEH is a referral-based eye clinic with advanced diagnostic testing and management of eye disease by optometrists and ophthalmologists.²⁸ Participants were excluded if they had uncontrolled systemic hypertension (>140 mm Hg systolic

BP and/or >90 mm Hg diastolic BP in office)²⁹ or joint pain precluding hand-squeezing to ensure safety and compliance. All participants provided written informed consent for research use of their deidentified data approved by the Biomedical Human Research Ethics Advisory Panel of the University of New South Wales and conforming to the tenets of the Declaration of Helsinki.

Interventions

The diagnostic interventions of this trial were the use of OCTA with the IHGT (intervention A) or without the IHGT (intervention B). OCTA imaging was performed by one of the authors (MT) with the Cirrus HD-OCT 5000 (Carl Zeiss Meditec, Jena, Germany) using the 6 × 6-mm macular cube with eye tracking and follow-up mode. Author MT was masked (both visually via a physical barrier and audibly via 32-dB noise reduction earmuffs [Vanderfield, Queensland, Australia]) to the intervention administered by author JN to the participant. Participants were advised to grip the dynamometer (Constant digital hand dynamometer; Camry, Zhongshan, China) with their elbow at 90°, resting on their lap.^{30,31} All patients were dilated with tropicamide eye drops an hour prior, and room lighting was turned off during scan acquisition.

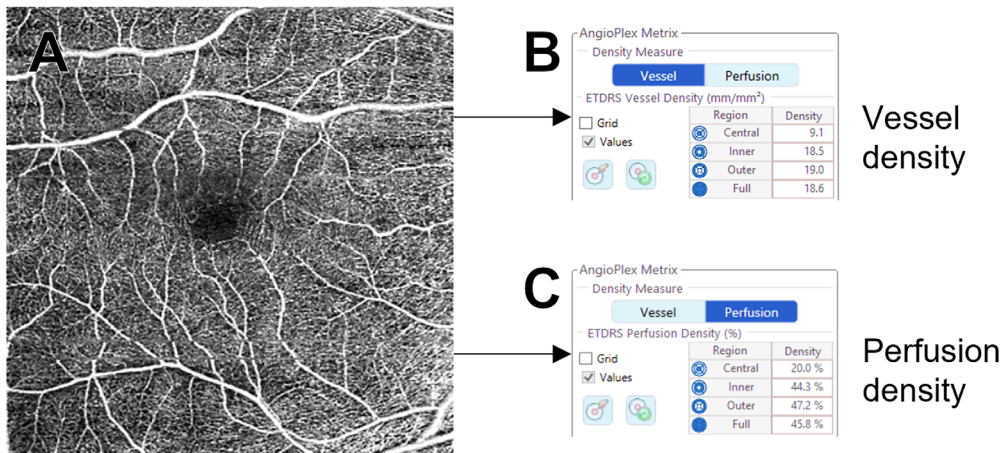
Outcomes

The primary outcome was OCTA signal quality as reported from the default Angioplex software (Carl Zeiss Meditec, Jena, Germany). This was measured as signal strength index (SSI; integer out of 10).

The secondary outcomes were other measures of vascular flow, including:

- OCTA:
 - En face vessel density (VD; %) from the default Angioplex software (Figs. 1A, 1B).
 - En face perfusion density (PD; %) from the default Angioplex software (Figs. 1A, 1C).
 - B-scan vascular flow signal ($\Delta\%$; percentage change of pixels from baseline), that is, two-color vascular flow signal across each of the 350 B-scans per macular volume from the default Angioplex software (Fig. 1D). Retinal (red; Fig. 1E) and choroidal (green; Fig. 1F) vascular flow signals were separated in “CIE Lab” color space and counted in pixels using ImageJ v1.52a (National Institutes of Health, Bethesda, MD, USA) without any further image processing. This analysis was defined a priori and included as a previous study had found the effect of the IHGT

En face vascular flow



B-scan vascular flow

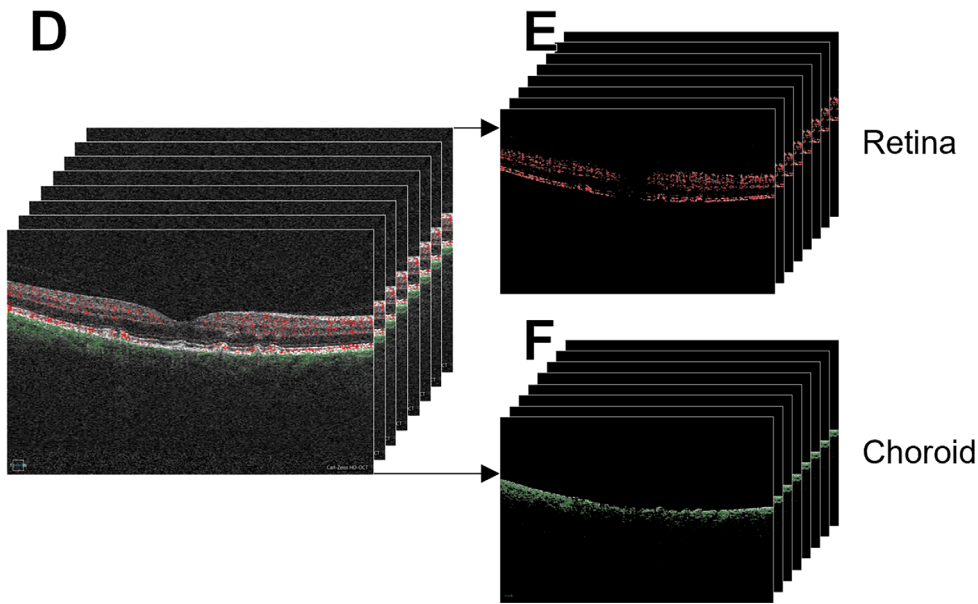


Figure 1. OCTA measures of vascular flow. Including OCTA en face vessel density (A, B) and perfusion density (C) from the default AngioPlex software, as well as B-scan vascular flow signal across the macular volume (D) for the retina (E) and choroid (F). B-scan vascular flow signal was derived from the default AngioPlex software and separated into retinal and choroidal signals using ImageJ. OCTA measures were compared with the IHGT versus without the IHGT.

- to be more pronounced on B-scan rather than en face OCTA imaging.¹⁸
- Systemic BP:
 - Systolic BP (mm Hg) = maximum blood pressure during ventricular contraction.³²
 - Diastolic BP (mm Hg) = minimum blood pressure during ventricular relaxation.³²

- Heart rate (bpm) = heart beats per minute.³³
- Perfusion pressure (mm Hg) = blood pressure force per contraction (systolic BP – diastolic BP).³⁴
- Mean arterial pressure (mm Hg) = average arterial pressure throughout the cardiac cycle (diastolic BP + one-third perfusion pressure).³⁴

Study Protocol, Randomization, and Masking

Eligible participants were allocated with concealment by JN to intervention sequence AB or BA using computerized, simple randomization via www.sealedenvelope.com (trial name “SQUEEZE crossover trial”). Maintenance of the computerized randomization of participants was performed by an independent colleague.

Participants completed a basic questionnaire, noting the standard intake of caffeine, alcohol, or cigarettes in the last 24 hours and the time of waking.^{35–38} The dynamometer was then set up in a random hand of the participant, while the sphygmomanometer was set up on the alternate arm. Baseline BP was measured, and then the participant was asked to squeeze at maximum grip strength (also known as maximum voluntary contraction) for 3 seconds. A 1-minute washout period before and after each intervention was selected a priori to ensure that BP returned to baseline levels after squeezing the dynamometer and that repeated BP measures were valid.^{39–41}

For intervention sequence AB, participants then squeezed and held the dynamometer at 50% maximum grip strength.⁸ After 1 minute, author JN then remeasured BP and author MT concurrently took two OCTA scans.⁴² After a 1-minute washout period, the process was repeated without the participant holding the dynamometer. Intervention sequence BA was performed in reverse order. A 50% maximum grip strength was selected to provide a margin for participants to maintain grip strength above the necessary 20% to induce a sympathetic response⁸ and minimize the time required for squeezing (subsequently minimizing the impact on clinical workflow).

Statistical Analyses

The targeted total sample size was 34 eyes from 34 participants. This was based on prestudy sampling analysis at CFEH and a trial design for two-tailed comparison, 0.05 alpha, 0.8 power, 20% attrition, and a primary outcome difference of one OCTA signal quality (out of 10) to yield a clinically significant change.^{4–6}

Preliminary analyses⁴³ involved assessing:

- OCTA repeatability of the two successive scans per interventions A and B with paired *t*-tests, to justify averaging of successive scan data to reduce noise.⁴² Test–retest reliability was assessed using a two-way mixed model with absolute agreement.⁴⁴

- Potential carryover effect by comparing systemic BP between baseline and intervention B (OCTA without the IHGT) with paired *t*-test.
- Potential period effect by comparing SSI mean differences between sequence AB and BA with paired *t*-test. Note that the potential sequence effect was mitigated by using randomized, masked sequence allocation,⁴³ thus accounting for time-of-intervention effects such as dry eyes or learning effects.

Primary crossover analysis (using OCTA signal quality as the primary outcome) was performed with a generalized linear mixed-model approach,⁴⁵ accounting for period and intervention fixed effects and individual within-participants random effects.

Secondary (nested) crossover analyses (using other measures of vascular flow as the secondary outcomes) were performed with paired *t*-tests in the absence of significant period effects.

Relationships between outcome changes versus covariables were also assessed using multivariable linear regression with backward stepwise elimination.⁴⁶ OCTA signal quality was assessed against person- and eye-level covariables. Systemic BP was assessed against person-level covariables only. These included:

- Person-level covariables of age, sex, self-reported race/ethnicity,⁴⁷ presence of cardiovascular disease including hypertension,⁴⁸ caffeine/alcohol/cigarette intake in the last 24 hours, time since waking, IHGT hand laterality, and maximum grip strength
- Eye-level covariables of spherical equivalent refraction, intraocular pressure,⁴⁹ aided visual acuity, and study eye laterality

Default statistical significance was denoted as a two-sided $P < 0.05$. All continuous variables were expressed as mean (95% confidence interval [CI]). All statistical analyses were performed using GraphPad Prism Version 9.5.1 (GraphPad Software, La Jolla, CA, USA), SPSS Version 25 (SPSS, Inc., Chicago, IL, USA), and Microsoft Excel Version 2203 (Microsoft, Redmond, WA, USA). The Mann–Whitney *U* test was performed in place of unpaired *t*-tests for nonnormal data. The Wilcoxon test was performed in place of paired *t*-tests for nonnormal data.

Results

Study Population

The CONSORT participant flow diagram is shown in Figure 2. A total of 36 participants were analyzed, whereby recruitment finished on the day of meeting target sample size. Using simple randomization, 16 participants were allocated to sequence AB (OCTA with the IHGT and then without the IHGT), and 20 were allocated to sequence BA. No participants dropped out or reported any adverse events.

Baseline participant demographics and clinical characteristics are summarized in Table 1. In brief, participants were 61.89 (57.93–65.86) years of age, 42% were female (15/21 female/male), and most were of white race/ethnicity (18/9/0/2 white/Asian/black/other). Aided visual acuities ranged from logarithm of the minimum angle of resolution

–0.1 to 1.3. The specific macular diagnoses of this population included age-related macular degeneration, choroidal naevi, diabetic retinopathy, epiretinal membrane, macular dystrophies, pachychoroid spectrum disease, and vitreomacular tractional disease (Supplementary Table S1).

Primary Analysis

OCTA Repeatability

To determine whether successive scans could be averaged, we assessed for systematic differences between successive OCTA outcomes for each intervention (Supplementary Table S2). There were no significant differences, and repeatability ranged from poor to excellent (intra-class correlation (ICC), 0.22–0.94) but was mostly moderate (ICC, 0.5–0.75) or good (ICC, 0.75–0.9). Subsequently, successive OCTA scan outcomes were averaged for all further analyses.⁴²

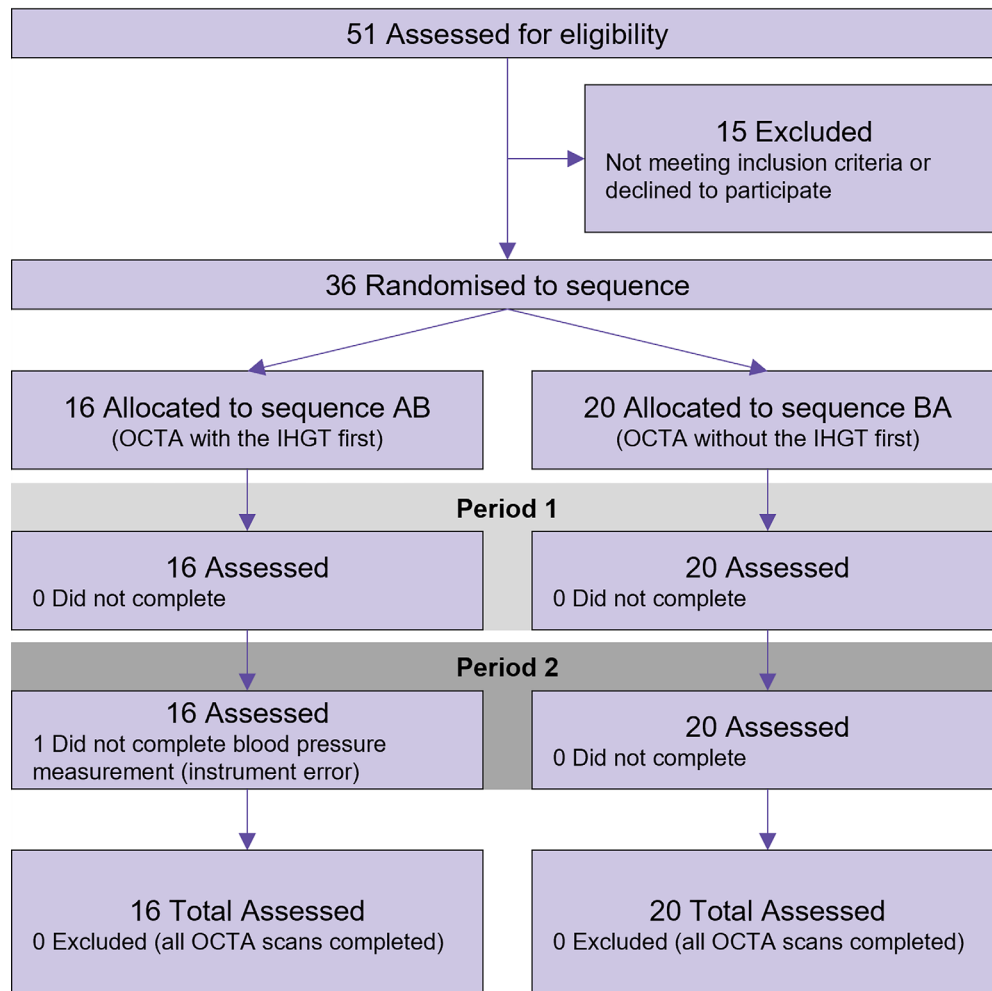


Figure 2. CONSORT flow diagram of participants.

Table 1. Baseline Participant Demographics and Clinical Characteristics by Sequence and by Total, Reported According to CONSORT Guidelines²⁶

Demographics and Characteristics	Sequence AB (OCTA With and Then Without the IHGT)	Sequence BA (OCTA Without and Then With the IHGT)	Total
Participants, <i>n</i>	16	20	36
Age, y	62.33 (55.4 to 69.26)	61.55 (56.44 to 66.66)	61.89 (57.93 to 65.86)
Sex (F/M)	6/10	9/11	15/21
Refraction (diopters)	−1.52 (−3.79 to 0.76)	0.73 (−0.17 to 1.63)	−0.25 (−1.37 to 0.86)
Intraocular pressure (mm Hg)	14.14 (12.47 to 15.82)	13.83 (12.53 to 15.14)	13.97 (12.99 to 14.94)
Visual acuity (aided; logMAR)	0.14 (−0.06 to 0.34)	0.15 (0.03 to 0.27)	0.15 (0.04 to 0.25)
Race/ethnicity (white/Asian/black/Other) ^a	6/6/0/1	12/3/0/1	18/9/0/2
Presence of cardiovascular disease	6/10	11/9	17/19
Caffeine intake in last 24 hours (standard drinks)	1 (0.49 to 1.52)	0.8 (0.41 to 1.19)	0.89 (0.59 to 1.19)
Alcohol intake in last 24 hours (standard drinks)	0.38 (0 to 0.76)	0.15 (0 to 0.38)	0.25 (0.05 to 0.45)
Cigarette intake in last 24 hours (standard cigarettes)	0.19 (0 to 0.48)	0.75 (0 to 2.3)	0.5 (0 to 1.35)
Time since waking (h)	7.5 (6.14 to 8.86)	6.82 (5.69 to 7.95)	7.12 (6.29 to 8)
Study eye laterality (right/left)	10/6	7/13	17/19
IHGT hand laterality (right/left)	7/9	12/8	19/17
Maximum grip strength (kg)	27.81 (23.8 to 31.81)	25.15 (20.96 to 29.34)	26.33 (23.51 to 29.15)

Continuous variables expressed as mean (95% confidence interval). logMAR, logarithm of the minimum angle of resolution.

^aRace/ethnicity was self-reported and had seven undisclosed values.

Carryover Effect

To mitigate potential carryover effect (i.e., whether effects from the first intervention may have carried over to the second intervention), a washout time of 1 minute was selected a priori.³⁹ The validity of this washout time and lack of carryover effect between interventions was confirmed as there were no significant differences ($P = 0.08$ – 0.54) for any systemic BP measures between baseline and intervention B (OCTA without the IHGT).

Primary Outcome

To test for a period effect on the primary outcome (i.e., whether the same intervention at different time periods may have affected OCTA signal quality), mean differences between interventions A and B were compared between sequences. OCTA signal quality was significantly higher in sequence AB (when OCTA with the IHGT was performed first) than sequence BA (mean difference, 0.69 [0.08–1.3], $P < 0.05$). Subsequently, the period effect was adjusted for in crossover analysis.

Mean OCTA signal quality of intervention A (OCTA with the IHGT) was 9.18 (8.89–9.64), and intervention B (OCTA without the IHGT) was 9.28 (8.86–9.56) (Table 2). Crossover analysis between interventions A and B adjusting for the period effect showed no significant OCTA signal quality mean difference by intervention (−0.09 [−0.6 to 0.42], $P = 0.71$) or by period × intervention interaction ($P = 0.73$), implying that the IHGT did not alter OCTA signal quality.

Secondary Analyses

Secondary Outcomes

Nested crossover analysis of other OCTA measures of vascular flow revealed that B-scan retinal vascular flow signal was significantly increased with the IHGT versus without the IHGT (mean difference, 2.95 [−1.64 to 7.55] $\Delta\%$, $P < 0.05$; Table 2). All other secondary OCTA measures of vascular flow, including en face vessel density, en face perfusion density, and B-scan choroidal vascular flow signal, were not significantly altered by the IHGT ($P = 0.19$ – 0.98). No period effects were evident for any of the secondary OCTA measures of vascular flow ($P = 0.08$ – 0.75).

Nested crossover analysis of non-OCTA/systemic measures of vascular flow showed a significant increase with the IHGT versus without the IHGT for systolic BP (12.38 [8.01–16.75] mm Hg, $P < 0.0001$), diastolic BP (7.44 [3.58–11.3] mm Hg, $P < 0.001$), pulse pressure (4.94 [0.41–9.47] mm Hg, $P < 0.05$), and mean arterial pressure (9.09 [5.66–12.51] mm Hg, $P < 0.0001$; Table 3). No period effects were evident for any of the systemic BP measures ($P = 0.28$ – 0.83). These secondary results confirmed that the IHGT induced a response in systemic BP, although most OCTA measures did not demonstrate a detectable change.

Multivariable Regression Analyses

Multivariable linear regression analyses were also performed to assess which factors may have impacted IHGT-induced changes in OCTA signal quality or

Table 2. Primary and Secondary Crossover Analyses of OCTA Measures

OCTA Signal Quality Measure	Mean Difference	P Value
Primary measure		
OCTA signal quality (/10)	−0.09 (−0.6 to 0.42)	0.71, 0.73 ^a
Secondary measures		
En face vessel density (global) (%)	−0.08 (−0.57 to 0.42)	0.71
Central	−1.32 (−4.4 to 1.77)	0.19
Inner ring	−1.1 (−3.47 to 1.27)	0.47
Outer ring	−1.09 (−3.12 to 0.95)	0.55
En face perfusion density (global) (%)	−0.26 (−3.08 to 2.56)	0.51
Central	−0.21 (−5.08 to 4.66)	0.82
Inner ring	0.34 (−3.16 to 3.83)	0.98
Outer ring	0.32 (−2.48 to 3.12)	0.86
B-scan retinal vascular flow signal ($\Delta\%$)	2.95 (−1.64 to 7.55)	<0.05
B-scan choroidal vascular flow signal ($\Delta\%$)	−0.19 (−2.97 to 2.6)	0.72

Mean differences presented as the change in OCTA vascular flow from using the IHGT.

Bold values represent statistical significance ($P < 0.05$).

^a P values are for period effect adjustment and period \times intervention adjustment, respectively.

Table 3. Secondary Nest Crossover Analysis of Systemic Blood Pressure

Systemic Blood Pressure Measure	Mean Difference	P Value
Systolic blood pressure (mm Hg)	12.38 (8.01 to 16.75)	<0.0001
Diastolic blood pressure (mm Hg)	7.44 (3.58 to 11.3)	<0.001
Heart rate (bpm)	1.71 (−1.32 to 4.73)	0.26
Pulse pressure (mm Hg)	4.94 (0.41 to 9.47)	<0.05
Mean arterial pressure (mm Hg)	9.09 (5.66 to 12.51)	<0.0001

Mean differences presented as the change in systemic blood pressure from using the IHGT.

Bold values represent statistical significance ($P < 0.05$).

other measures of vascular flow. For OCTA outcomes, OCTA signal quality changes were positively associated with sex (females; regression coefficient, 1.04 [0.24–1.85], $P < 0.05$) and refraction (0.17 [0.04–0.3], $P < 0.05$; Supplementary Table S3). En face vessel density and perfusion density changes were negatively associated with Asian race/ethnicity (compared to white and other; -1.54 [−2.87 to -0.21] and -3.95 [−7.39 to -0.51], respectively, $P < 0.05$) and positively associated with right-hand IHGT use (1.08 [0.16 to 2] and 2.8 [0.43 to 5.18], respectively, $P < 0.05$). No other person- or eye-level factors impacted IHGT-induced changes in OCTA outcomes.

For systemic BP, systolic BP, diastolic BP, and mean arterial pressure were generally positively associated with right-hand IHGT use (7.17 [−0.77 to 15.12] to 10.3 [3.59 to 17.01], $P < 0.01$ to 0.07) and maximum grip strength (0.35 [−0.06 to 0.77] to 0.58 [0.09 to 1.06], $P < 0.05$ to 0.09; Supplementary Table S4). No other person-level factors impacted IHGT-induced changes in systemic BP. These results highlight the modifiable factors (right-hand use and grip strength) that may help

induce a greater effect of the IHGT on systemic BP and, subsequently, ocular vascular flow.

Discussion

This randomized crossover pilot trial highlighted that performing the IHGT during OCTA imaging did not alter rudimentary OCTA signal quality (integer out of 10) but can increase OCTA B-scan retinal vascular flow signal for eyes with a range of macular abnormalities. Expectedly, measures of systemic BP were significantly increased by the IHGT, and two (likely interrelated) factors were associated with these changes—right (versus left) hand IHGT use and a greater maximum grip strength. These results suggest that the IHGT may enhance OCTA imaging quality for patients with adequate grip strength. Further research is required to determine if these results are generalizable to larger populations and if the visualization of specific OCTA biomarkers can be augmented.

The IHGT Can Augment OCTA Retinal Vascular Flow Signal in Eyes With Abnormal Macula

Retinal vascular blood flow is myogenically auto-regulated by local pericytes, which maintain retinal vascular resistance against the ophthalmic artery's perfusion pressure.⁵⁰ Thus, despite lacking autonomic innervation like the choroid,⁵¹ the retinal vasculature can still respond to changes in ocular perfusion pressure and metabolic demand.⁵² This was supported by the results of our study, as we highlighted that OCTA B-scan retinal vascular flow signal was significantly increased by the IHGT in eyes with abnormal macula. Increased retinal vascular flow signal did not lead to significant alterations in OCTA signal quality, but the latter is a coarse measure (on a scale of 1 to 10) with nontransparent/proprietary understanding of its calculation⁵³ and may therefore be insensitive to subtle retinal vascular changes. Other studies of eyes with healthy and diseased maculae have reported conflicting retinal vascular changes in response to the IHGT,^{10,11} including decreased retinal vascular flow signal possibly due to local vasoconstriction.^{12,13} These discrepancies may relate to differing study criteria for "healthy" and "diseased" maculae and/or different vascular imaging protocols and timing, particularly as blood flow is highly dynamic. Specifically, isometric exercise is believed to induce both reactive vasoconstriction and vasodilation,^{54,55} depending upon the time frame of image capture. Nonetheless, both studies suggest that the IHGT can significantly alter OCTA retinal vascular signal, although the exact chronology of events (regarding increased and/or decreased flow signal) remains uncertain.

A recent study demonstrated that IHGT-induced changes were more evident on three-dimensional than two-dimensional OCTA imaging.¹⁸ Relatedly, our results found that the IHGT induced changes in B-scan retinal vascular flow signal but not en face measures of vascular flow. This may have been due to data loss/compression from quantifying two- versus three-dimensional imaging, as research has shown that the latter is less susceptible to erroneous segmentation,⁵⁶ depth-related artifacts, and multilayered signal loss.⁵⁶ Surprisingly in our study, however, B-scan choroidal vascular flow signal also did not show significant change with the IHGT, although this may have related to reduced penetration of the spectral-domain (versus swept-source) OCT employed.⁵⁷ Future studies in larger populations that exploit the benefits of three-dimensional OCTA data⁵⁸⁻⁶⁴ would help to clarify findings.

IHGT-Induced Changes to Systemic BP Are Linked to Absolute Grip Strength

Acute IHGT-induced changes in central and peripheral blood pressure have been well established,^{8,65-73} likely caused by the abrupt increase in arterial pressure⁹ from autonomic adjustments such as tachycardia (increased cardiac output)²³ and changes in vessel diameter.²⁰⁻²² We highlighted that nonmodifiable factors, including sex (females), refraction, and race/ethnicity (white and other versus Asian) were positively associated with IHGT-induced changes in vascular flow, confirming the importance of considering these factors in future studies and potentially in clinical practice.

Curiously, we found that modifiable factors, including maximum grip strength and (likely interrelated) right-hand IHGT use,⁷⁴ were positively associated with increases in various OCTA and systemic measures of vascular flow. This was in contrast to previous research, which suggests that the pressor response is relative to the intensity of isometric exercise,⁸ meaning that a frail, older patient and an athletic, younger patient both squeezing at 20% of their maximum capacities should elicit the same systemic vascular response. In this study, all participants should have squeezed at 50% of their maximum grip strength, although we could not quantify how compliant participants were with maintaining this. Nonetheless, our finding has significant practical implications as the effects of the IHGT may then be untenable in patients with reduced hand-squeezing capacity (e.g., in the frail and elderly population and particularly those with rheumatoid arthritis). The positive association of right-hand IHGT use with increases in systemic BP may have been interrelated to the maximum grip strength as the general population⁷⁴ has greater right-handed grip strength⁷⁵ and/or may relate to the greater shear stress experienced on the right aortic valve wall.^{76,77} Thus, adjusting for hand dominance in future studies utilizing the IHGT is needed.

Limitations

The primary limitation of this pilot study was the recruitment of a small convenience sample of participants with macular abnormalities referred into a single ophthalmic imaging center. We could not draw definitive conclusions as to whether there may have been a ceiling effect of OCTA signal quality (which could not exceed 10/10) or a floor effect from low grip strength. Additionally, participants could not enter this pilot trial with uncontrolled systemic hypertension due to safety reasons, thus excluding

those who may have elicited greater responses to the IHGT (and subsequently strengthened our results) due to compromised retinal vasculature.⁷⁸ Similarly, macular diagnoses were heterogeneous and ranged from relatively benign epiretinal membranes to vision-threatening neovascularization, and this study was not adequately powered to perform subgroup analysis of specific macular disease entities. Further studies in larger, homogeneous disease populations are currently under way to address these limitations and adequately power further analyses of potential OCTA changes in response to varying strength and duration⁷⁹ of the IHGT.

Second, OCTA has not yet been integrated into standard clinical practice, and as such, the clinical translation of statistically significant results is still uncertain. While the repeatability of successive OCTA scans was generally moderate to good (albeit some cases of poor repeatability may have been due to unmeasured factors such as tear film quality),²⁵ we could not compare our findings against test–retest 95% limits of agreement to assess clinical relevance, due to nonnormal distribution of differences.⁸⁰ Further study is also warranted to assess the potential impact of performing OCTA with the IHGT on the detection of specific biomarkers, such as branching capillaries in neovascularization⁸¹ of varying etiologies.

Conclusions

The IHGT may be a useful addition to the OCTA imaging protocol for individuals with macular abnormalities, due to an induced increase in B-scan retinal vascular flow signal. IHGT-induced changes, however, are associated with right-hand use and maximum grip strength and, therefore, may be less effective in patients with low grip strength. Further work with a larger population is needed to clarify if the IHGT may be useful in augmenting the visualization of specific OCTA biomarkers.

Acknowledgments

The authors thank Natalie Eshow for maintaining the computerized randomization of participants and the research participants for providing their time.

Supported by the National Health and Medical Research Council of Australia (grant 1174385; LN-S). The funding body had no influence on any aspect of

study design, data collection, analysis, or interpretation.

Disclosure: **M. Trinh**, None; **J. Nam**, None; **M. Kumar**, None; **L. Nivison-Smith**, None

References

1. Kornblau IS, El-Annan JF. Adverse reactions to fluorescein angiography: a comprehensive review of the literature. *Surv Ophthalmol*. 2019;64(5):679–693, doi:10.1016/j.survophthal.2019.02.004.
2. Shea AM, Curtis LH, Hammill BG, et al. Resource use and costs associated with diabetic macular edema in elderly persons. *Arch Ophthalmol*. 2008;126(12):1748–1754, doi:10.1001/archophth.126.12.1748.
3. Munk MR, Kashani AH, Tadayoni R, et al. Standardization of OCT angiography nomenclature in retinal vascular diseases: first survey results. *Ophthalmol Retina*. 2021;5(10):981–990, doi:10.1016/j.oret.2020.12.022.
4. Yu JJ, Camino A, Liu L, et al. Signal strength reduction effects in OCT angiography. *Ophthalmol Retina*. 2019;3(10):835–842, doi:10.1016/j.oret.2019.04.029.
5. Lim HB, Kim YW, Nam KY, Ryu CK, Jo YJ, Kim JY. Signal strength as an important factor in the analysis of peripapillary microvascular density using optical coherence tomography angiography. *Sci Rep*. 2019;9(1):16299, doi:10.1038/s41598-019-52818-x.
6. Czakó C, István L, Benyó F, et al. The impact of deterministic signal loss on OCT angiography measurements. *Transl Vis Sci Technol*. 2020;9(5):10, doi:10.1167/tvst.9.5.10.
7. Al-Sheikh M, Ghasemi Falavarjani K, Akil H, Sadda SR. Impact of image quality on OCT angiography based quantitative measurements. *Int J Retina Vitre*. 2017;3:13, doi:10.1186/s40942-017-0068-9.
8. Seals DR, Chase PB, Taylor JA. Autonomic mediation of the pressor responses to isometric exercise in humans. *J Appl Physiol Bethesda Md*. 1985 1988;64(5):2190–2196, doi:10.1186/s40942-017-0068-9.
9. Lind AR, McNicol GW. Circulatory responses to sustained hand-grip contractions performed during other exercise, both rhythmic and static. *J Physiol*. 1967;192(3):595–607.
10. Gocuk SA, Hadoux X, Catipon C, et al. Retinal vascular reactivity in carriers of X-linked inher-

- ited retinal disease—a study using optical coherence tomography angiography. *Invest Ophthalmol Vis Sci.* 2023;64(8):3677.
11. Sousa DC, Leal I, Moreira S, et al. A protocol to evaluate retinal vascular response using optical coherence tomography angiography. *Front Neurosci.* 2019;13:566, doi:[10.3389/fnins.2019.00566](https://doi.org/10.3389/fnins.2019.00566).
 12. Barcroft H, Millen JLE. The blood flow through muscle during sustained contraction. *J Physiol.* 1939;97(1):17–31.
 13. Ewing DJ, Martyn CN, Young RJ, Clarke BF. The value of cardiovascular autonomic function tests: 10 years experience in diabetes. *Diabetes Care.* 1985;8(5):491–498, doi:[10.2337/diacare.8.5.491](https://doi.org/10.2337/diacare.8.5.491).
 14. Riva CE, Titze P, Hero M, Movaffagh A, Petrig BL. Choroidal blood flow during isometric exercises. *Invest Ophthalmol Vis Sci.* 1997;38(11):2338–2343.
 15. Tittl M, Maar N, Polska E, Weigert G, Stur M, Schmetterer L. Choroidal hemodynamic changes during isometric exercise in patients with inactive central serous chorioretinopathy. *Invest Ophthalmol Vis Sci.* 2005;46(12):4717–4721, doi:[10.1167/iovs.05-0268](https://doi.org/10.1167/iovs.05-0268).
 16. Piccolino FC, Lupidi M, Cagini C, et al. Choroidal vascular reactivity in central serous chorioretinopathy. *Invest Ophthalmol Vis Sci.* 2018;59(10):3897–3905, doi:[10.1167/iovs.18-23995](https://doi.org/10.1167/iovs.18-23995).
 17. Piccolino FC, Lupidi M, Cagini C, et al. Retinal vascular reactivity in central serous chorioretinopathy. *Invest Ophthalmol Vis Sci.* 2018;59(11):4425–4433, doi:[10.1167/iovs.18-24475](https://doi.org/10.1167/iovs.18-24475).
 18. Lupidi M, Fruttini D, Eandi CM, et al. Chronic neovascular central serous chorioretinopathy: a stress/rest optical coherence tomography angiography study. *Am J Ophthalmol.* 2020;211:63–75, doi:[10.1016/j.ajo.2019.10.033](https://doi.org/10.1016/j.ajo.2019.10.033).
 19. Okuno T, Sugiyama T, Kohyama M, Kojima S, Oku H, Ikeda T. Ocular blood flow changes after dynamic exercise in humans. *Eye.* 2006;20(7):796–800, doi:[10.1038/sj.eye.6702004](https://doi.org/10.1038/sj.eye.6702004).
 20. Eklund B, Kaijser L, Knutsson E. Blood flow in resting (contralateral) arm and leg during isometric contraction. *J Physiol.* 1974;240(1):111–124, doi:[10.1113/jphysiol.1974.sp010602](https://doi.org/10.1113/jphysiol.1974.sp010602).
 21. Rusch NJ, Shepherd JT, Webb RC, Vanhoutte PM. Different behavior of the resistance vessels of the human calf and forearm during contralateral isometric exercise, mental stress, and abnormal respiratory movements. *Circ Res.* 1981;48(6 Pt 2):118–130.
 22. Saito M, Mano T, Abe H, Iwase S. Responses in muscle sympathetic nerve activity to sustained hand-grips of different tensions in humans. *Eur J Appl Physiol.* 1986;55(5):493–498, doi:[10.1007/BF00421643](https://doi.org/10.1007/BF00421643).
 23. Martin CE, Shaver JA, Leon DF, Thompson ME, Reddy PS, Leonard JJ. Autonomic mechanisms in hemodynamic responses to isometric exercise. *J Clin Invest.* 1974;54(1):104–115.
 24. Sedrakyan A, Marinac-Dabic D, Normand S-LT, Mushlin A, Gross T. A framework for evidence evaluation and methodological issues in implantable device studies. *Med Care.* 2010;48(6 Suppl):S121–S128, doi:[10.1097/MLR.0b013e3181d991c4](https://doi.org/10.1097/MLR.0b013e3181d991c4).
 25. Lee WH, Lim HB, Kim J, Ryu CK, Shin YI, Kim JY. Repeatability of macular microvasculature measurements using optical coherence tomography angiography according to tear breakup time in dry eye disease. *Retina.* 2021;41(11):2301–2309, doi:[10.1097/IAE.0000000000003177](https://doi.org/10.1097/IAE.0000000000003177).
 26. Dwan K, Li T, Altman DG, Elbourne D. CONSORT 2010 statement: extension to randomised crossover trials. *BMJ.* 2019;366:l4378, doi:[10.1136/bmj.l4378](https://doi.org/10.1136/bmj.l4378).
 27. Maclure M. The case-crossover design: a method for studying transient effects on the risk of acute events. *Am J Epidemiol.* 1991;133(2):144–153, doi:[10.1093/oxfordjournals.aje.a115853](https://doi.org/10.1093/oxfordjournals.aje.a115853).
 28. Wang H, Kalloniatis M. Clinical outcomes of the Centre for Eye Health: an intra-professional optometry-led collaborative eye care clinic in Australia. *Clin Exp Optom.* 2021;104(7):795–804, doi:[10.1080/08164622.2021.1878821](https://doi.org/10.1080/08164622.2021.1878821).
 29. Unger T, Borghi C, Charchar F, et al. 2020 International Society of Hypertension global hypertension practice guidelines. *Hypertension.* 2020;75(6):1334–1357, doi:[10.1161/HYPERTENSIONAHA.120.15026](https://doi.org/10.1161/HYPERTENSIONAHA.120.15026).
 30. Balogun JA, Akomolafe CT, Amusa LO. Grip strength: effects of testing posture and elbow position. *Arch Phys Med Rehabil.* 1991;72(5):280–283.
 31. Su CY, Lin JH, Chien TH, Cheng KF, Sung YT. Grip strength in different positions of elbow and shoulder. *Arch Phys Med Rehabil.* 1994;75(7):812–815.
 32. Shahoud JS, Sanvictores T, Aeddula NR. *Physiology, Arterial Pressure Regulation.* Treasure Island, FL: StatPearls Publishing; 2022. Accessed March 1, 2023, <http://www.ncbi.nlm.nih.gov/books/NBK538509/>.
 33. Oberman R, Bhardwaj A. *Physiology, Cardiac.* Treasure Island, FL: StatPearls Publishing; 2022. Accessed March 1, 2023, <http://www.ncbi.nlm.nih.gov/books/NBK526089/>.

34. Chaudhry R, Miao JH, Rehman A. *Physiology, Cardiovascular*. Treasure Island, FL: StatPearls Publishing; 2022. Accessed March 1, 2023, <http://www.ncbi.nlm.nih.gov/books/NBK493197/>.
35. Ayhan Z, Kaya M, Ozturk T, Karti O, Hakan Oner F. Evaluation of macular perfusion in healthy smokers by using optical coherence tomography angiography. *Ophthalmic Surg Lasers Imaging Retina*. 2017;48(8):617–622, doi:10.3928/23258160-20170802-03.
36. Karimi S, Arabi A, Shahraki T. Alcohol and the eye. *J Ophthalmic Vis Res*. 2021;16(2):260–270, doi:10.18502/jovr.v16i2.9089.
37. Karti O, Zengin MO, Kerici SG, Ayhan Z, Kusbeci T. Acute effect of caffeine on macular microcirculation in healthy subjects: an optical coherence tomography angiography study. *Retina*. 2019;39(5):964–971, doi:10.1097/IAE.0000000000002058.
38. Müller VC, Storp JJ, Kerschke L, Nelis P, Eter N, Alnawaiseh M. Diurnal variations in flow density measured using optical coherence tomography angiography and the impact of heart rate, mean arterial pressure and intraocular pressure on flow density in primary open-angle glaucoma patients. *Acta Ophthalmol*. 2019;97(6):e844–e849, doi:10.1111/aos.14089.
39. Muntner P, Shimbo D, Carey RM, et al. Measurement of blood pressure in humans: a scientific statement from the American Heart Association. *Hypertension*. 2019;73(5):e35–e66, doi:10.1161/HYP.0000000000000087.
40. Pickering TG, Hall JE, Appel LJ, et al. Recommendations for blood pressure measurement in humans and experimental animals: part 1: blood pressure measurement in humans: a statement for professionals from the Subcommittee of Professional and Public Education of the American Heart Association Council on High Blood Pressure Research. *Circulation*. 2005;111(5):697–716, doi:10.1161/01.CIR.0000154900.76284.F6.
41. Koehler NR, Poli de Figueiredo CE, Mendes-Ribeiro AC. Time interval between pairs of arterial blood pressure measurements—does it matter? *Am J Hypertens*. 2004;17(2):194–196, doi:10.1016/j.amjhyper.2003.08.013.
42. Uji A, Balasubramanian S, Lei J, Baghdasaryan E, Al-Sheikh M, Sadda SR. Impact of multiple en face image averaging on quantitative assessment from optical coherence tomography angiography images. *Ophthalmology*. 2017;124(7):944–952, doi:10.1016/j.optha.2017.02.006.
43. Lim C-Y, In J. Considerations for crossover design in clinical study. *Korean J Anesthesiol*. 2021;74(4):293–299, doi:10.4097/kja.21165.
44. Koo TK, Li MY. A guideline of selecting and reporting intraclass correlation coefficients for reliability research. *J Chiropr Med*. 2016;15(2):155–163, doi:10.1016/j.jcm.2016.02.012.
45. Putt M, Chinchilli VM. A mixed effects model for the analysis of repeated measures crossover studies. *Stat Med*. 1999;18(22):3037–3058, doi:10.1002/(sici)1097-6660258(19991130)18:22(3037::aid-sim243)3.0.co;2-7.
46. Derksen S, Keselman HJ. Backward, forward and stepwise automated subset selection algorithms: frequency of obtaining authentic and noise variables. *Br J Math Stat Psychol*. 1992;45(2):265–282, doi:10.1111/j.2044-8317.1992.tb00992.x.
47. Moore DB. Reporting of race and ethnicity in the ophthalmology literature in 2019. *JAMA Ophthalmol*. 2020;138(8):903–906, doi:10.1001/jamaophthalmol.2020.2107.
48. Harrison JE, Weber S, Jakob R, Chute CG. ICD-11: an international classification of diseases for the twenty-first century. *BMC Med Inform Decis Mak*. 2021;21(Suppl 6):206, doi:10.1186/s12911-021-01534-6.
49. Lal B, Alonso-Caneiro D, Read SA, et al. Changes in retinal optical coherence tomography angiography indexes over 24 hours. *Invest Ophthalmol Vis Sci*. 2022;63(3):25, doi:10.1167/iovs.63.3.25.
50. Pournaras CJ, Rungger-Brändle E, Riva CE, Hardarson SH, Stefansson E. Regulation of retinal blood flow in health and disease. *Prog Retin Eye Res*. 2008;27(3):284–330, doi:10.1016/j.preteyeres.2008.02.002.
51. Luo X, Shen Y-M, Jiang M-N, Lou X-F, Shen Y. Ocular blood flow autoregulation mechanisms and methods. *J Ophthalmol*. 2015;2015:864871, doi:10.1155/2015./864871.
52. Harris A, Ciulla TA, Chung HS, Martin B. Regulation of retinal and optic nerve blood flow. *Arch Ophthalmol*. 1998;116(11):1491–1495, doi:10.1001/archophth.116.11.1491.
53. Zeiss Meditec, Inc. *C. Cirrus HD-OCT User Manual—Models 500,5000*. Carl Zeiss Meditec, Inc.; 2017; CA, USA.
54. Rickson JJ, Maris SA, Headley SAE. Isometric exercise training: a review of hypothesized mechanisms and protocol application in persons with hypertension. *Int J Exerc Sci*. 2021;14(2):1261–1276.
55. Cotzias C, Marshall JM. Differential effects of isometric exercise on the cutaneous circulation of dif-

- ferent regions. *Clin Auton Res.* 1992;2(4):235–241, doi:10.1007/BF01819544.
56. Borrelli E, Parravano M, Sacconi R, et al. Guidelines on optical coherence tomography angiography imaging: 2020 focused update. *Ophthalmol Ther.* 2020;9(4):697–707, doi:10.1007/s40123-020-00286-2.
 57. Stanga PE, Tsamis E, Papayannis A, Stringa F, Cole T, Jalil A. Swept-source optical coherence tomography angio (Topcon Corp, Japan): technology review. *Dev Ophthalmol.* 2016;56:13–17, doi:10.1159/000442771.
 58. Cabral D, Pereira T, Ledesma-Gil G, et al. Volume rendering of dense b-scan optical coherence tomography angiography to evaluate the connectivity of macular blood flow. *Invest Ophthalmol Vis Sci.* 2020;61(6):44, doi:10.1167/iovs.61.6.44.
 59. Nesper PL, Soetikno BT, Treister AD, Fawzi AA. Volume-rendered projection-resolved OCT angiography: 3D lesion complexity is associated with therapy response in wet age-related macular degeneration. *Invest Ophthalmol Vis Sci.* 2018;59(5):1944–1952, doi:10.1167/iovs.17-23361.
 60. Borrelli E, Sacconi R, Querques L, Battista M, Bandello F, Querques G. Quantification of diabetic macular ischemia using novel three-dimensional optical coherence tomography angiography metrics. *J Biophotonics.* 2020;13(10):e202000152, doi:10.1002/jbio.202000152.
 61. Borrelli E, Sacconi R, Klose G, de Sisternes L, Bandello F, Querques G. Rotational three-dimensional OCTA: a notable new imaging tool to characterize type 3 macular neovascularization. *Sci Rep.* 2019;9(1):17053, doi:10.1038/s41598-019-53307-x.
 62. Borrelli E, Sacconi R, Brambati M, Bandello F, Querques G. In vivo rotational three-dimensional OCTA analysis of microaneurysms in the human diabetic retina. *Sci Rep.* 2019;9(1):16789, doi:10.1038/s41598-019-53357-1.
 63. Spaide RF. Volume-rendered angiographic and structural optical coherence tomography. *Retina.* 2015;35(11):2181–2187, doi:10.1097/IAE.0000000000000764.
 64. Spaide RF, Klancknik JM, Cooney MJ, et al. Volume-rendering optical coherence tomography angiography of macular telangiectasia type 2. *Ophthalmology.* 2015;122(11):2261–2269, doi:10.1016/j.ophtha.2015.07.025.
 65. Tanaka S, Sugiura T, Yamashita S, Dohi Y, Kimura G, Ohte N. Differential response of central blood pressure to isometric and isotonic exercises. *Sci Rep.* 2014;4(1):5439, doi:10.1038/srep05439.
 66. Ogbutor GU, Nwangwa EK, Uyagu DD. Isometric handgrip exercise training attenuates blood pressure in prehypertensive subjects at 30% maximum voluntary contraction. *Niger J Clin Pract.* 2019;22(12):1765, doi:10.4103/njcp.njcp_240_18.
 67. Lydakis C, Momen A, Blaha C, et al. Changes of central haemodynamic parameters during mental stress and acute bouts of static and dynamic exercise. *J Hum Hypertens.* 2008;22(5):320–328, doi:10.1038/jhh.2008.4.
 68. Khurana RK, Setty A. The value of the isometric hand-grip test-studies in various autonomic disorders. *Clin Auton Res.* 1996;6(4):211–218, doi:10.1007/BF02291136.
 69. Karthikkeyan K, Latha K, Gokulnathan V. Effects of isometric handgrip exercise on blood pressure and its role in identifying hypertensive risk individuals. *Int J Contemp Med Res IJCMR.* 2020;7(2):B1–B4, doi:10.21276/ijcmr.2020.7.2.4.
 70. Bond V, Curry BH, Adams RG, et al. Cardiovascular responses to an isometric handgrip exercise in females with prehypertension. *North Am J Med Sci.* 2016;8(6):243, doi:10.4103/1947-2714.185032.
 71. Gnanadurai TK, Vajravelu HR, Krishnan PRB, Ayyavoo SR, Jr. Assessment of sympathetic nerve activity by isometric handgrip test in young cigarette smokers. *Biomed Pharmacol J.* 2016;9(2):623–629.
 72. Rowland T, Fernhall B. Cardiovascular responses to static exercise: a re-appraisal. *Int J Sports Med.* 2007;28(11):905–908, doi:10.1055/s-2007-965063.
 73. Hietanen E. Cardiovascular responses to static exercise. *Scand J Work Environ Health.* 1984;10(6 Spec No):397–402, doi:10.5271/sjweh.2304.
 74. Tan U. The distribution of hand preference in normal men and women. *Int J Neurosci.* 1988;41(1–2):35–55, doi:10.3109/00207458808985740.
 75. Incel NA, Ceceli E, Durukan PB, Erdem HR, Yorgancioglu ZR. Grip strength: effect of hand dominance. *Singapore Med J.* 2002;43(5):234–237.
 76. Peng H, Yang D. A boundary element analysis on hemodynamic characteristics at the bifurcation of abdominal arterial. *Sheng Wu Yi Xue Gong Cheng Xue Za Zhi.* 2012;29(4):697–700.
 77. Shan Y, Li J, Wang Y, et al. Aortic shear stress in patients with bicuspid aortic valve with stenosis and insufficiency. *J Thorac Cardiovasc Surg.* 2017;153(6):1263–1272.e1, doi:10.1016/j.jtcvs.2016.12.059.
 78. Besharati MR, Rastegar A, Shoja MR, Maybodi ME. Prevalence of retinopathy in hypertensive patients. *Saudi Med J.* 2006;27(11):1725–1728.
 79. McDougal DH, Gamlin PD. Autonomic control of the eye. *Compr Physiol.* 2015;5(1):439–473.

80. Doğan NÖ. Bland-Altman analysis: a paradigm to understand correlation and agreement. *Turk J Emerg Med.* 2018;18(4):139–141, doi:[10.1016/j.tjem.2018.09.001](https://doi.org/10.1016/j.tjem.2018.09.001).
81. Hsu CR, Lai TT, Hsieh YT, Ho TC, Yang CM, Yang CH. Combined quantitative and

qualitative optical coherence tomography angiography biomarkers for predicting active neovascular age-related macular degeneration. *Sci Rep.* 2021;11(1):18068, doi:[10.1038/s41598-021-97652-2](https://doi.org/10.1038/s41598-021-97652-2).