tvst

Article

Novel Surgical Pathway for Controlled Access to the Subretinal Space: A Case Series

Khalid Al Sabti[1] **and Seemant Raizada**[1]

[1] Kuwait Specialized Eye Center, Kuwait City, Kuwait

Correspondence: Seemant Raizada, Kuwait Specialized Eye Center, Block 8, Street 80, Shaab Al Bahiri, Kuwait City, Kuwait.
e-mail: seemantdr@gmail.com

Received: October 5, 2021
Accepted: March 14, 2022
Published: April 13, 2022

Keywords: subretinal space; fourth 25G valved cannula; subretinal fibrosis removal

Citation: Sabti KA, Raizada S. Novel surgical pathway for controlled access to the subretinal space: A case series. Transl Vis Sci Technol. 2022;11(4):11, https://doi.org/10.1167/tvst.11.4.11

Purpose: We report a case series demonstrating a novel technique to access the subretinal space through a trans-scleral approach.

Methods: This was a prospective, interventional case series. All 25 cases underwent three-port vitrectomy using CONSTELLATION Vision System (Alcon. Laboratories, Inc., Fort Worth, TX) and NGENUITY 3D Visualization System. In all cases a fourth 25G valved cannula was inserted posteriorly in the vitreous cavity to secure a controlled access to the subretinal space. This route was used to remove subretinal fibrosis, drain subretinal fluid, and inject vital dye to identify an occult retinal break in some cases.

Results: In 23 of 25 cases, the retina remained attached postoperatively after a single surgery, and vision improvement was observed. In two cases, the retina was attached after an additional procedure. Although mild subretinal hemorrhage was seen in three cases, no other major complication was observed.

Conclusions: Access to the subretinal space by a posteriorly placed fourth valved cannula is safe and helps in subretinal fibrosis removal and drainage of subretinal fluid and can be useful in complicated retinal detachments.

Translational Relevance: This case series uses knowledge acquired from developing small gauge microincision instruments for pars plana vitrectomy to present a novel clinical application applicable to difficult, complex retinal surgeries.

Introduction

Vitreoretinal surgeons require access to the subretinal space for various reasons during surgical procedures, the most common being drainage of subretinal fluid (SRF) through a trans-scleral route. Several SRF drainage techniques have been described in the literature.[1–3] McLeod[2] performed posterior trans-scleral drainage of SRF using a 20G needle monitored by indirect ophthalmoscopy. The Charles[3] technique using a 25G needle and an automated system for external drainage is associated with conventional scleral buckling. Ryan et al.[4] used an argon endolaser probe to create a choroidotomy for drainage of SRF in 200 scleral buckling surgeries. Recently, Kitchens[5] used a 26G needle guarded with a buckle sleeve to drain SRF via a trans-scleral route. Siqueira et al.[6] described a technique of transconjunctival retinopexy with external drainage of SRF using an active aspiration vacuum.

Newer techniques for accessing the subretinal space have been developed with the advent of microsurgical instruments. The introduction of transconjunctival microincision vitrectomy surgery with 25G to 27G instrumentation has resulted in easier and faster pars plana vitrectomy (PPV).[7–12] In 2010, Oshima et al.[7] introduced the sutureless 27G PPV system. Using these microincision vitrectomy instruments, Li et al.,[13] demonstrating a novel technique for trans-scleral drainage of SRF using a 25G trocar-valved cannula in patients with Coats' disease and severe exudative retinal detachment. Wolff[14] described an innovative approach to accessing the subretinal space. He used a standard 23G or 25G valved cannula inserted posteriorly into the vitreous cavity corresponding with the highest fluid level. This valved cannula was used to remove SRF as well as subretinal fibrosis using intravitreal forceps.

A substantial amount of time and effort has been put into developing small gauge microincision instruments for PPV. This case series uses that knowledge

Copyright 2022 The Authors

This work is licensed under a Creative Commons Attribution-NonCommercial-NoDerivatives 4.0 International License.

Downloaded from intl.iovs.org on 04/25/2024

to create a novel clinical application that can assist in selected, complex, and difficult retinal surgeries. A standard PPV often consists of three ports of entry into the vitreous cavity. We used a fourth microincision cannula to gain controlled valved access to the subretinal space in carefully selected cases. Through this valved cannula, 25G intraocular forceps were used to remove subretinal fibrosis, a 25G back-flush needle was used to drain the SRF, or vital dye was injected to identify an occult retinal break.

Methods

Twenty-five patients were enrolled in this prospective, interventional case series at a tertiary care eye center. The surgical procedures described herein were performed in carefully selected cases. Inclusion criteria were Coats disease with chronic exudative detachment, retinal detachment in cases of high myopes with an axial length of more than 32 mm, and chronic retinal detachment or redetachments after an initial PPV with subretinal fibrosis. Cases where a conventional PPV could be done easily were excluded from our study. We also excluded cases on blood thinners like aspirin or clopidogrel, cases with uncontrolled hypertension, and patients with any blood dyscrasias. A standard three-port vitrectomy was completed in all cases using the CONSTELLATION Vision System (Alcon Laboratories, Inc., Fort Worth, TX) and NGENUITY 3D Visualization System with DATAFUSION (Alcon Laboratories). In all 25 cases, a fourth 25G valved cannula was inserted posteriorly into the vitreous cavity to secure a controlled access to the subretinal space. The study was conducted in accordance with the Declaration of Helsinki and was approved by the appropriate institutional review board. All participants provided written informed consent.

Trans-Scleral Vacuum-Assisted Drainage of SRF

When the SRF is viscous, passive drainage does not work. In the first seven cases, we used a fourth 25G valved cannula mounted on a trocar to posteriorly enter the vitreous cavity under the detached retina. The location of insertion of the fourth 25G cannula was chosen according to the height of the detached retina, the location of the subretinal fibrosis, and the ease of approach. In the majority of cases, we inserted the fourth cannula where the SRF level was highest to avoid inadvertent retinal incarceration in our cannula or back-flush needle. We went with temporal approach in all cases owing to the ease of entry and safety profile. We selected our cases carefully with a higher level of SRF on the temporal side. The fourth trocar–cannula should not be inserted further than the vascular arcade in the posterior pole of the fundus, but there is no fixed distance from the limbus. Usually, the fourth trocar–cannula was inserted 10 to 16 mm distance from limbus (Figs. 1 A1, A2). We try to place it as anteriorly as possible but sometimes we had to go beyond 15 mm from the limbus, behind the scleral buckle (Figs. 1 B1, B2). Placing the fourth cannula more posterior than 16 mm from limbus will interfere with the smooth opening of the forceps blade as well as kink the 25G instruments. We did not place the fourth cannula in nasal quadrant because of less freedom of movement in the nasal side compared with the temporal quadrant of the eye. If a fourth cannula is placed posteriorly on the nasal side, it may cause kinking of small gauge instruments when introduced through the cannula. Retinal detachments with extensive nasal subretinal bands should be avoided with this technique. Cases where nasal subretinal bands extend to the temporal quadrant can be taken out by forceps introduced through a temporarily placed fourth cannula. Nasal subretinal bands not extensive or not causing extensive contraction of retina can be left during the surgery. While placing the cannula, try to avoid the 3 and 9 o'clock segments because a long ciliary neurovascular complex runs through that area. Also, the area around the vortex veins should be avoided when placing the fourth cannula. Once we visually confirmed that the cannula had entered the subretinal space, the trocar was removed, leaving the cannula in place. Because this access to the subretinal space was valved, no SRF drained spontaneously, and the procedure was well-controlled. A 25G back-flush needle connected to a silicone oil removal kit on the vitrectomy machine (Alcon Constellation system; Alcon Laboratories) was used to drain viscous SRF. A 500-mm Hg linear vacuum was used to actively remove the fluid from the subretinal space. This active aspiration of the viscous SRF was done in three cases of Coats' disease and in four cases of chronic retinal detachment. All SRF drainage was done under constant visualization of the retina to detect any incarceration.

Trans-Scleral Vital Dye Injection to Identify Occult Retinal Breaks

For cases in which we could not identify the retinal break preoperatively or during the PPV, we used the trans-scleral route to access the subretinal space and inject Membrane Blue Dual (DORC International,

Downloaded from intl.iovs.org on 04/25/2024

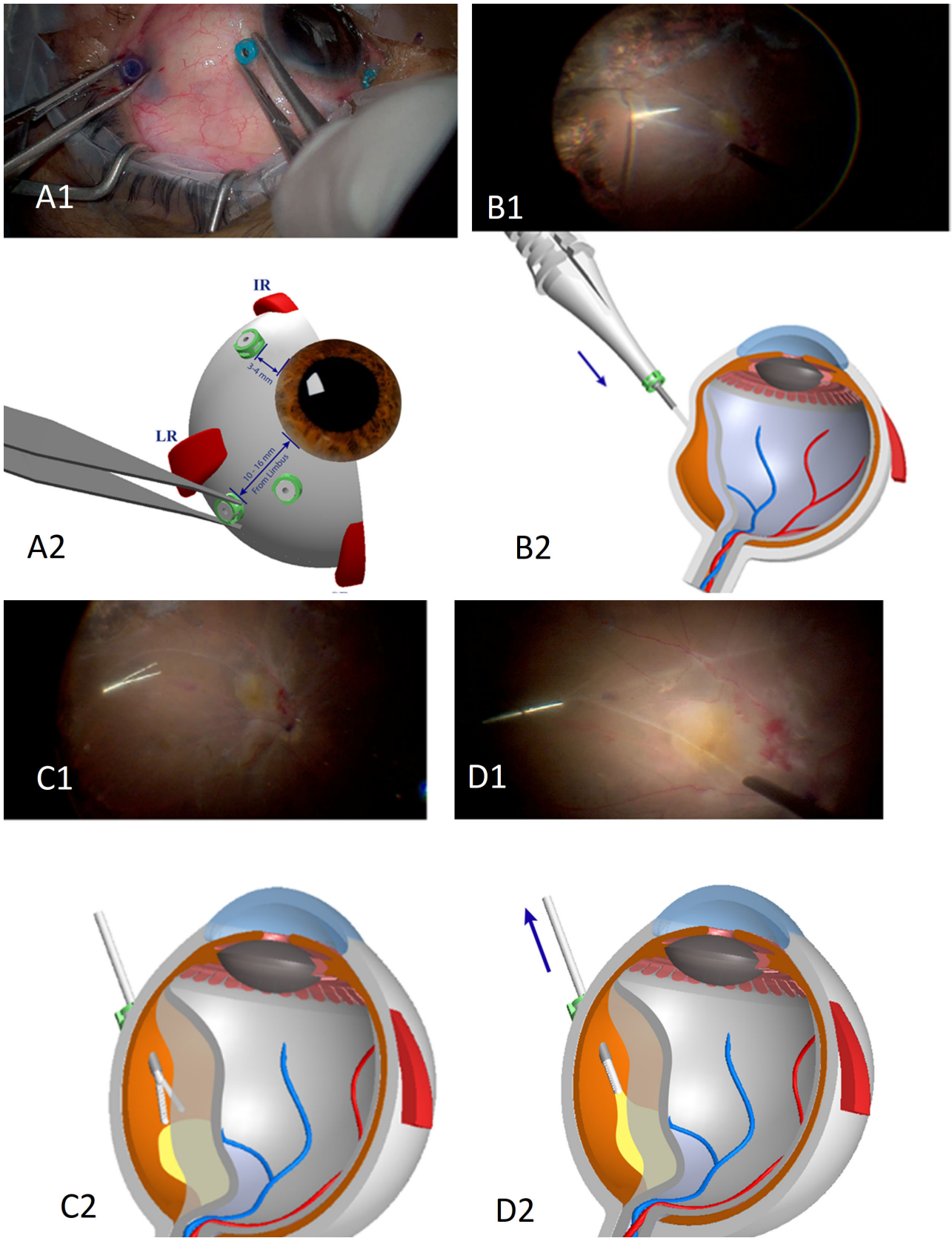

Figure 1. (A1) Picture showing the position of the fourth trocar–cannula in a representative case. The placement of fourth trocar is temporal and usually placed after assessing the SRF levels and ease of entry. Usually we keep it 12–16 mm from limbus. (A2) Graphic figure showing →

Downloaded from intl.iovs.org on 04/25/2024

←
the position of fourth trocar–cannula in relation to limbus and other trocar-cannula placements. (B1) Picture showing trocar entering the eye posterior to scleral buckle in a redetached retina after a failed previous PPV coupled with a scleral buckle. The trocar can be visualized under detached retina. (B2) Graphic art figure showing how the trocar enters behind the buckle indentation. This trocar-cannula creates a controlled valved access to the subretinal space. C1: Picture showing a 25G intraocular forceps inserted through a fourth trocar–cannula. The forceps can be seen in subretinal space approaching towards the subretinal fibrosis. (C2) Graphic art figure showing the position of the intraocular 25G forceps under retina. (D1) Picture showing a 25G intraocular forceps inserted through a fourth trocar–cannula. The forceps can be seen in subretinal space catching and puling the subretinal fibrotic bands. Note that it's a tangential pull and not anteroposterior as would happen in a conventional approach through a retinal hole or retinotomy. (D2) Graphic art figure showing 25G forceps holding the subretinal fibrosis under the retina and pulling it out of the fourth cannula without causing a new retinal tear or retinotomy.

Zuidland, the Netherlands) diluted 20% with balanced salt solution. Membrane Blue Dual is composed of 0.125 mg Brilliant Blue G and 0.75 mg trypan blue. First, a routine three-port PPV was performed. Then, we used a fourth 25G valved trocar cannula inserted posteriorly into the vitreous cavity where the SRF level was highest. The dye was injected in subretinal space of detached retina, that is, the SRF was stained with the diluted vital dye. The idea was to inject dye in SRF and see the egress of SRF from occult retinal hole in cases where we could identify retinal tear preoperatively or intraoperatively. Perfluorocarbon liquid (PFCL) was injected into the posterior pole to safeguard the macular area and avoid movement of the dye in the subretinal space under the macula. PFCL also helped in pushing the SRF toward the periphery, helping the SRF mixed with vital dye to egress from the occult retinal break.

Trans-Scleral Approach to Remove Subretinal Fibrosis or Bands

In chronic cases of retinal detachment or in cases of redetachments after a previous PPV, we used a posteriorly placed fourth 25G valved cannula and intraocular forceps (GRIESHABER MAXGRIP forceps) to remove subretinal fibrosis. The location was chosen according to the height of the detached retina, the location of the subretinal fibrosis, and the ease of approach. Max-grip forceps were then used to remove the s-bands (Figs. 1 C1, C2, D1, D2). Intraocular pressure was raised to 60 mm Hg to decrease the chances of choroidal bleeding. We used 25G instruments instead of 27G because 25G instruments are sturdier and more appropriate for holding tough subretinal fibrous bands; moreover, they do not bend when using a more posterior approach.

A video to enumerate the surgical steps of placing and inserting a fourth trocar–cannula along with the use of intraocular forceps to grasp and remove sub retinal fibrotic band has been included with the manuscript. The video also shows how this posteriorly placed fourth cannula was used to inject vital dye in the subretinal space to stain the SRF and to locate an occult retinal hole when the dye egresses out of it. Supplemental Digital Content 1.

Results

In the first seven cases, a fourth posteriorly placed 25G valved cannula and a 25G back flush needle were used to actively aspirate viscous SRF. The demographic characteristics, primary diagnosis, preoperative and final vision, and complications, if any, of these cases are shown in Table 1. Of these seven cases, one involved a chronic retinal detachment with high myopia, three involved recurrent retinal detachments, and three involved Coats' disease. The average follow-up was 9 months. Vision improvement was noted in five cases. One patient's vision remained equal to preoperative status, and another patient's vision declined postoperatively. This patient had retinal detachment with high myopia and posterior staphyloma. In two of these cases, membrane blue dye was injected into the subretinal space through a 25G valved cannula to locate the occult retinal hole. No major complications were noted in these cases, except for mild choroidal hemorrhage at the needle entry site in two cases.

In the next 18 cases of chronic retinal detachment or redetachment, we used a posteriorly placed fourth 25G valved cannula to achieve controlled access to the subretinal space. Twelve cases involved recurrent retinal detachment and six involved chronic detachment (three of which were due to trauma). The demographic characteristics, primary diagnoses, preoperative and final vision levels, and complications, if any, are shown in Table 2. Figure 2 shows fundus images of a patient with recurrent retinal detachment and subretinal fibrosis (Fig. 2A). This patient underwent PPV with subretinal fibrous tissue removal using intravitreal forceps (Fig. 2B) inserted through the fourth

translational vision science & technology

Downloaded from intl.iovs.org on 04/25/2024

Table 1. Trans-Scleral Vacuum-Assisted Drainage of SRF

	Age/Sex	Diagnosis	Preoperative Vn	Postoperative Final Vn	Procedure	Complication
1	54/F	High myopia chronic RD	Counting fingers	20/40	TPPV/C_3F_8	None
2	62/F	High myopia recurrent RD	20/300	20/400	TPPV/SOI	None
3	56/F	Recurrent RD	20/40	20/20	TPPV/SOI	Mild subretinal hemorrhage
4	47/M	Recurrent RD	20/100	20/100	TPPV/C_3F_8	None
5	3/M	Coats' Disease	Counting finger	20/80	TPPV	None
6	6/M	Coats' disease	20/400	20/60	TPPV	None
7	5/M	Coats' disease	20/400	20/100	TPPV	None

C_3F_8, octafluoropropane; CF, counting fingers; HM, hand motion; PL, perception of light; PVR, proliferative vitreoretinopathy. RD, retinal detachment; Re ED, recurrent retinal detachment; SOI, silicone oil injection; TPPV, trans-scleral PPV using a fourth trocar cannula

Table 2. Trans-Scleral Approach to Remove Subretinal Fibrosis/Bands

	Age/sex	Diagnosis	Preoperative Vn	Postoperative Final Vn	Procedure	Complication
1	64/M	RD+ PVR	20/150	20/400	TPPV/SOI	None
2	19/F	Recurrent RD	20/200	20/100	TPPV/C_3F_8	None
3	59/M	Recurrent RD	PL+	CF	TPPV/SOI	Mild subretinal hemorrhage
4	70/M	Recurrent RD	20/150	20/150	TPPV/C_3F_8	None
5	57/M	Recurrent RD	CF	20/200	TPPV/C_3F_8/SB	None
6	64/M	Recurrent RD	CF	20/100	TPPV/SOI	None
7	53/M	Recurrent RD	HM	PL	TPPV/SOI	Re RD
8	64/M	RD + PVR	HM	CF	TPPV/SOI	None
9	53/M	RD + PVR	HM	20/80	TPPV/C_3F_8	None
10	62/M	Recurrent RD	20/100	20/60	TPPV/C_3F_8	Mild subretinal hemorrhage
11	68/M	Recurrent RD	HM	20/100	TPPV/SOI	None
12	37/M	Recurrent RD	20/200	20/300	TPPV/C_3F_8	Re RD
13	65/F	Recurrent RD	CF	HM	TPPV/SOI/SB	None
14	37/M	RD + PVR	20/400	20/70	TPPV/SOI	None
15	61/M	RD + PVR	CF	20/200	TPPV/SOI/SB	None
16	60/M	Recurrent RD	CF	20/300	TPPV/SOI/SB	None
17	53/M	RD+ PVR	CF	20/80	TPPV/C_3F_8	None
18	56/M	Recurrent RD	PL+	20/200	TPPV/SOI	None

C_3F_8, octafluoropropane; CF, counting fingers; HM, hand motion; PL, perception of light; PVR, proliferative vitreoretinopathy; RD, retinal detachment; Re RD, recurrent retinal detachment; SB, scleral buckle; SOI, silicone oil injection; TPPV, trans-scleral PPV using a fourth trocar cannula

sclerotomy. Postoperatively, the retina was attached under silicone oil (Fig. 2C) with no obvious choroidal hemorrhage. Figure 2D shows the same patient 6 months later, after silicone oil removal. The patients' vision improved in 13 of the 18 cases. No change was observed between preoperative and postoperative vision in two cases, and vision decreased postoperatively in three cases. The fourth valved cannula was used in six cases to inject vital dye to locate an occult hole in the retina. Figure 3 shows the egress of vital dye from the subretinal space into the vitreous cavity through a small retinal hole. C_3F_8 gas was used in seven cases, whereas a silicone oil tamponade was used in 11. Redetachment after the first PPV was reported in two cases; both were reattached after another PPV and relaxing retinotomy procedure.

translational vision science & technology

Downloaded from intl.iovs.org on 04/25/2024

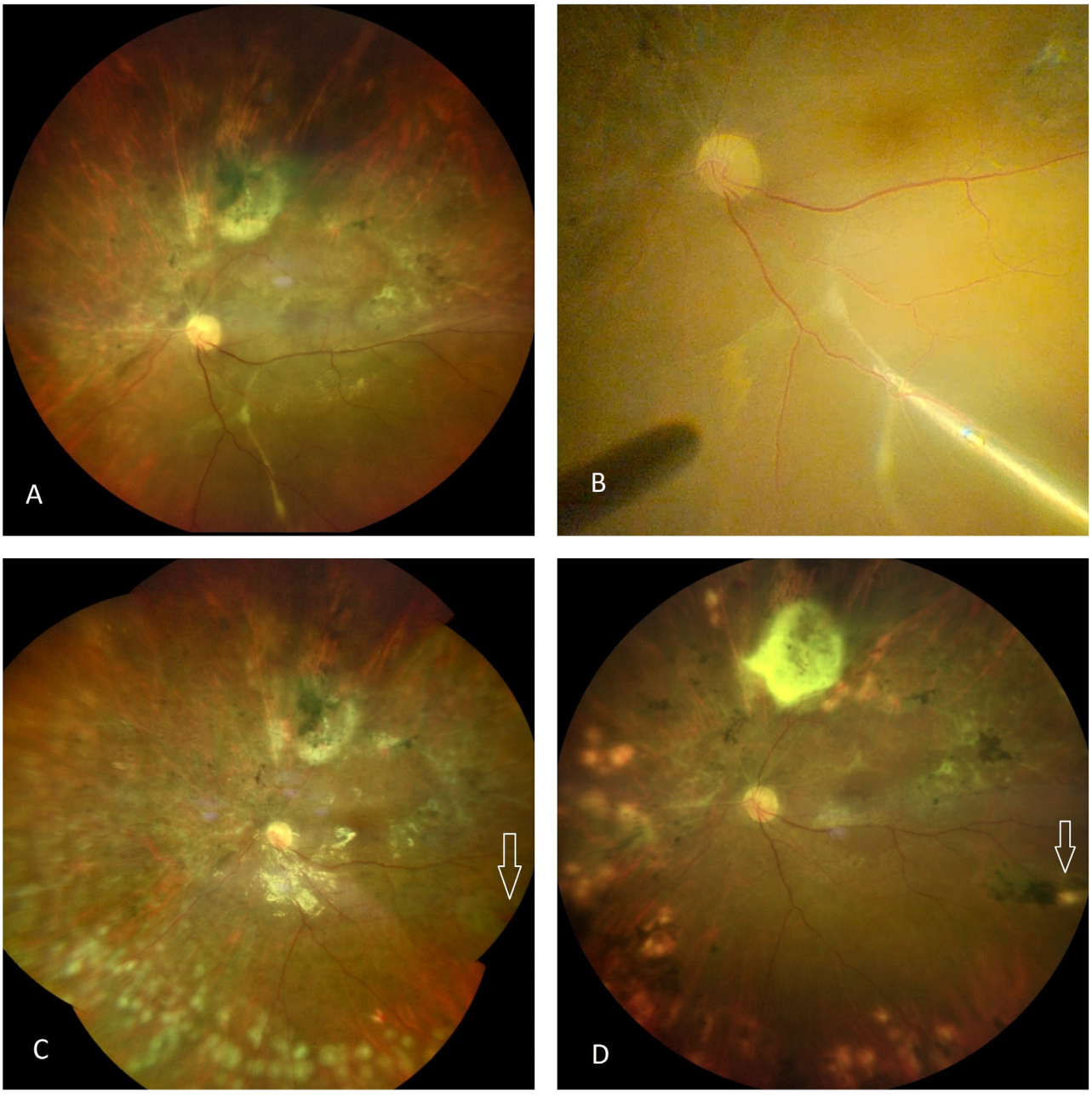

Figure 2. (2A) Preoperative fundus picture of patient with chronic retinal re-detachment showing subretinal fibrosis. (2B) Subretinal fibrosis caught by intraocular forceps entered through fourth trocar trans-scleral approach. (2C) First day postoperative fundus picture of same patient. Retina attached. White arrowhead showing small hemorrhage at the site of entry of forceps through trans-scleral route. No subretinal fibrosis seen. (2D) One-month postoperative fundus picture of same patient. Retina attached. White arrowhead showing the site of entry of forceps through trans-scleral route.

Discussion

The trans-scleral route to access the subretinal space is not new to retinal surgery. Burton et al.[15] compared trans-scleral needle drainage with the conventional two-stage drainage technique in a prospective clinical trial. They reported an 84% success rate for rhegmatogenous retinal detachment repair with one surgery using the trans-scleral approach to drain SRF by needle. However, subretinal hemorrhage occurred in 22% of the cases and blood extended subfoveally in four cases. The subretinal hemorrhage rate as described by Jaffe et al.[16] was 4%. In the present case series, we encountered choroidal bleeding or subretinal hemorrhage in 3 of the 18 cases. In all three of these

Downloaded from intl.iovs.org on 04/25/2024

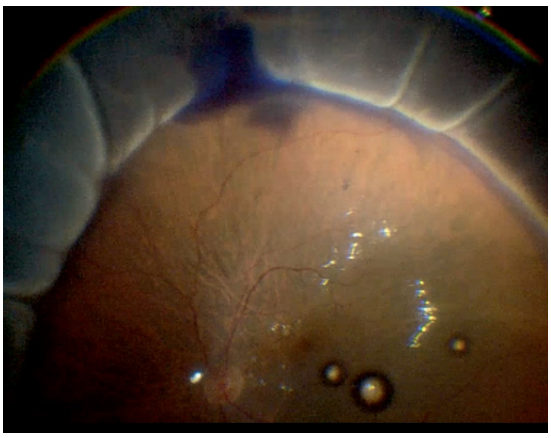

Figure 3. Subretinal vital dye is injected through trans-scleral route, via the fourth cannula, under the detached retina. The dye can be seen coming out in the vitreous cavity from an occult retinal break. Note that the macula and posterior pole of the retina is pushed back in place by perfluoro carbon liquid to avoid the dye to migrate posteriorly.

cases, subretinal bleeding stopped with an increase in infusion pressure from the vitrectomy machine. Transillumination from the light pipe can help to avoid choroidal hemorrhage, the most common complication of trans-scleral SRF drainage. Gärtner[17] and Freeman and Schepens[18] highlighted the use and advantages of transillumination during SRF drainage. Transillumination may be used to visualize and avoid larger choroidal vessels, although there remains a small risk of bleeding from the choriocapillaris. The endoilluminator should be on high light setting and room lights should be switched off for better contrast and visualization. After the core vitrectomy, an important tip to avoid complications is to protect the macula with PFCL. It serves two purposes. First, it prevents subretinal blood from migrating under the macula in the unlikely event of choroidal hemorrhage. Second, PFCL pushes the SRF to the periphery, which makes retinal detachment more bullous in peripheral part. This step will enable the insertion of the fourth trocar cannula easier and safer. Additionally, owing to an elevated retina, the likelihood of retinal incarceration will be decreased, when instruments are inserted through the fourth trocar.

SRF drainage in exudative detachments, as seen in Coats' disease, can be difficult owing to the high viscosity of the SRF. In a review of patients with advanced Coats' disease, Adam et al.[19] reported that external drainage with cryoablation or laser ablation was sufficient to reattach the retina. In their review of six patients treated with external drainage, only one had persistent SRF for up to 4 months; this patient underwent second surgery. Liag Li et al.[13] reported 20 cases of Coats' disease in which they drained SRF trans-sclerally using a 25G trocar–cannula with a self-closing valve. All the patients were given intravitreal anti-vascular endothelial growth factor injections. The authors concluded that their technique was less invasive and helped in early recovery, with good postoperative outcomes in patients with advanced stage 3B Coats' disease. In our series, we used active aspiration of the SRF via the trans-scleral route through a 25G needle in one case and through a fourth posteriorly placed 25G valved cannula and back flush needle in two cases of Coats' disease. All three cases of Coats' disease in our series resulted in an attached retina and improved vision. We started this technique of using a fourth trocar cannula, first in Coats disease cases where we wanted to avoid an iatrogenic retinotomy to drain viscous SRF. When we gained confidence and our learning curve plateaued, we started looking for cases where this new technique could assist. We selected cases with subretinal fibrosis, chronic retinal detachments, and redetachments.

One of the most common causes of failed primary rhegmatogenous retinal detachment surgery is failure to identify all the full-thickness defects in the retina. Careful retinal examination by an experienced vitreoretinal surgeon remains the best method for detecting retinal breaks; nevertheless, there are cases in which no break can be identified before or during surgery, especially if the media is not clear. Hence, a technique that improves retinal-break detection would be a useful adjunct to vitreoretinal surgery. Because we were already using a fourth posteriorly placed cannula in our complicated retinal detachment cases, in eight of these cases we used the fourth cannula to inject a vital dye in the subretinal space. Our trans-scleral technique using a fourth posteriorly placed 25G valved cannula to stain the SRF was helpful when we could not find the retinal break preoperatively. The first subretinal application of dyes to stain retinal breaks was reported by Black[20] in 1947. He used methylene blue through a trans-scleral needle. Gupta et al.[21] described injection of subretinal trypan blue (Vision Blue, 0.006% version of trypan blue, DORC International) into the SRF using a 30G needle. Jackson et al.[22] elaborated on this subretinal dye injection technique by injecting 0.15% trypan blue with a 41G cannula designed for macular translocation surgery to identify retinal breaks in patients with retinal detachment and no identifiable tears during surgery. In their series, retinal breaks were identified in four of five patients, and no retinal toxicity was observed. However, the small number of patients does not allow for an assessment of the risks and potential toxicity. The dye provides color contrast that aids in the detection of occult retinal

Downloaded from intl.iovs.org on 04/25/2024

holes. Moreover, in some instances, the dye stains the devitalized tissue of the break itself. We were able to identify occult retinal breaks in all eight cases in which we used this technique. All these cases involved recurrent retinal detachment, and the valved 25G cannula was used not only to inject dyes but also to drain SRF. In addition, this fourth cannula was used for removal of subretinal bands with 25G forceps when required. Retinal toxicity remains a potential complication, especially because some dye may be left in the subretinal space. However, Veckeneer et al.[23] investigated the toxicity of trypan blue at various concentrations (0.2% and 0.06%) and found signs of toxicity only at 0.2%, manifested as damaged photoreceptors and marked disorganization with light and electron microscopy and decreased immunohistochemical staining with rhodopsin. The heavy membrane blue-dual dye has been used commonly for macular hole surgery. In a study of human retinal pigment epithelial cells, Januschowski et al.[24] used electrophysiological evaluations to show that heavy dye applied for up to 5 minutes had no harmful effects on retinal ganglion cells. In a retrospective comparative case series, Kovacević et al.[25] also reported successful surgical results with membrane blue-dual dye. We used the membrane blue-dual dye diluted 20% with balanced salt solution and injected PFCL into the vitreous cavity to limit migration of heavy dye under the macula and further decrease the chances of toxicity. Efforts to remove the dye by internal drainage would only debulk the dye rather than completely remove it. We were able to completely remove the subretinal dye via active aspiration through the fourth 25G valved cannula (a silicone-tipped extrusion cannula).

In 18 cases, we used a trans-scleral approach to remove subretinal fibrosis in cases of chronic retinal detachment. Partial core vitrectomy was performed, and induction of posterior vitreous detachment was avoided at that time to limit free movement of the retina. A freely mobile retina after posterior vitreous detachment is at greater risk of moving toward the valved cannula during instrument insertion. We wanted the retina to be relatively stiff when we use the fourth 25G valved cannula to access the subretinal space. Wolff[14] described this technique in a single case report; he placed a scleral buckle without doing PPV in a young patient with chronic detachment. The biggest advantage of our trans-scleral approach is that we can avoid multiple iatrogenic retinotomies when removing subretinal fibrosis. These retinotomies increase in size when subretinal fibrotic tissue is pulled through them owing to vertical traction caused by pulling the subretinal fibrotic bands upward through a conventional pars plana cannula approach. Multiple large tears in an already compromised retina with significant fibrosis or proliferative vitreoretinopathy will decrease the reattachment rate of the retina. Another advantage of our trans-scleral technique is that when we pull the subretinal fibrotic bands through posteriorly placed cannula, we exert a tangential pull on the subretinal bands and not an anteroposterior pull if we go through anteriorly placed pars plana cannula. This tangential pull allows the complete removal of subretinal fibrotic bands through a single opening; it does not break while being pulled out. Because placing a fourth cannula posteriorly involves going through the scleral wall and choroid, subretinal bleeding is a possibility. We encountered subretinal bleeding in 3 of our 25 cases. In these three cases, the subretinal bleeding subsided spontaneously with an increase in infusion pressure; there was also no significant bleeding during the postoperative period. There is a remote chance of development of choroidal neovascular membrane at the point of entry of fourth trocar-cannula owing to disruption of Bruch's membrane. Compared with choroidal neovascularization in age-related macular degeneration, the course of traumatic neovascular membranes is relatively benign. Because these choroidal neovascularizations are a consistent part of the ocular repair mechanism they usually regress spontaneously as part of the healing process.[26] Not much is reported regarding the development of a choroidal neovascular membrane after retinal detachment surgeries. In a recent study, Nagaradh et al.[26] reported an 0.6% incidence of choroidal neovascular membrane development after retinal detachment surgery in their case series. We did not encounter any such complication in our study, where cases were followed up for up to 9 months postoperatively.

In this case series, we describe novel techniques to access the subretinal space in carefully selected cases. This controlled access route can be used for the drainage of the SRF, especially in very high myopia, in exudative detachment with viscous fluid, to stain subretinal space to identify occult retinal breaks, and for complete removal of subretinal fibrosis without creating retinotomies. Theoretically, possible complications of trans-scleral insertion of instruments include hypotony, choroidal hemorrhage, retinal hemorrhage, retinal and vitreous incarceration, and choroidal neovascular membrane formation later in postoperative period. The creation of an iatrogenic break is also possible and would render the technique less effective if it occurs. We believe that in carefully selected cases, this trans-scleral access to subretinal space with the assistance of microincision 25G and 27G instruments, will be a useful adjunct for retinal surgeons.

Downloaded from intl.iovs.org on 04/25/2024

Acknowledgments

Disclosure: **K. Al Sabti,** None; **S. Raizada,** None

References

1. Williams GA, Aaberg TM. Techniques of scleral buckling. Vol 3. In: Ryan SJ, Glaser BM, eds. *Retina*. St. Louis: Mosby; 1994;1979–2033.
2. McLeod D. Monitored posterior transcleral drainage of subretinal fluid. *Br J Ophthalmol.* 1985;69:433–434.
3. Charles ST. Controlled drainage of subretinal and choroidal fluid. *Retina*. 1985;5:233–234.
4. Ryan EH, Arribas NP, Olk RJ, et al. External argon laser drainage of subretinal fluid using the endolaser probe. *Retina*. 1991;11:214–218.
5. Kitchens, JW. Modified external needle drainage of subretinal fluid in the management of rhegmatogenous retinal detachment using a "guarded needle" approach. *Arch Ophthalmol.* 2011;129:949–951.
6. Siqueira RC, Jorge R, Scott IU. Transconjunctival retinopexy with active external drainage of subretinal fluid: a prospective pilot study of eight consecutive cases. *Arq Bras Oftalmol.* 2007;70:573–576
7. Oshima Y, Wakabayashi T, Sato T, et al. A 27-gauge instrument system for trans conjunctival sutureless microincision vitrectomy surgery. *Ophthalmology*. 2010;117:93–102.
8. Rizzo S, Barca F, Caporossi T, Mariotti C. Twenty-seven gauge vitrectomy for various vitreoretinal diseases. *Retina*. 2015;35:1273–1278.
9. Fujii GY, De Juan E, Jr, Humayun MS, et al. A new 25-gauge instrument system for transconjunctival sutureless vitrectomy surgery. *Ophthalmology*. 2002;109:1807–1812.
10. Lakhanpal RR, Humayun MS, de Juan E, Jr, et al. Outcomes of 140 consecutive cases of 25-gauge transconjunctival surgery for posterior disease. *Ophthalmology*. 2005;112:817–824.
11. Ibarra MS, Hermel M, Prenner JL, Hassan TS. Long term outcomes of transconjunctival sutureless 25-gauge vitrectomy. *Am J Ophthalmol*. 2005;139:831–836.
12. Eckardt C. Transconjunctival sutureless 23-gauge vitrectomy. *Retina*. 2005;25:208–211.
13. Li L, Li S-F, Liu J-H, et al. Novel transscleral sutureless subretinal fluid drainage using a 25-gauge trocar-cannula with a self-closing valve in patients with advanced Coats disease. *Int J Ophthalmol*. 2019;12:1444–1449.
14. Wolff B. Subretinal surgery ab externo: a novel approach to access the subretinal space without the need for retinotomy. *Retina*. 2015;35:1474–1475.
15. Burton RL, Cairns JD, Campbell WG, et al. Needle drainage of subretinal fluid: a randomized clinical trial. *Retina*. 1993;13:13–16.
16. Jaffe GJ, Brownlow R, Hines J. Modified external needle drainage procedure for rhegmatogenous retinal detachment. *Retina*. 2003;23:80.
17. Gärtner, J. Microsurgical release of subretinal fluid in retinal detachment. Report on 200 cases. *Klin Monbl Augenheilkd.* 1976;168:761–768
18. Freeman HM, Schepens CL. Innovations in technique for drainage of subretinal fluid: transillumination and choroidal diathermy. *Trans Am Acad Ophthalmol OtolaryngoI*. 1974;78:829–836.
19. Adam RS, Kertes PJ, Lam WC. Observations on the management of Coats' disease: less is more. *Br J Ophthalmol.* 2007;91:303–306.
20. Black GW. Some aspects of the treatment of simple detachment of the retina, including vital staining of the retina by methylene blue. *Trans Ophthalmol Soc UK.* 1947;67:313–322.
21. Gupta, D, Ong J, Burton RL. Trans-scleral dye injection during vitreous surgery to identify clinically undetectable retinal breaks causing retinal detachment. *Eye*. 2011;25:1045–1049.
22. Jackson TL, Kwan AS, Laidlaw AH, Aylward W. Identification of retinal breaks using subretinal trypan blue injection. *Ophthalmology*. 2007;114:587–590.
23. Veckeneer M, van Overdam K, Monzer J, et al. Ocular toxicity study of trypan blue injected into the vitreous cavity of rabbit eyes. *Graefes Arch Clin Exp Ophthalmol*. 2001;239:698–704.
24. Januschowski K, Mueller S, Spitzer MS, et al. Investigating the biocompatibility of two new heavy intraocular dyes for vitreoretinal surgery with an isolated perfused vertebrate retina organ culture model and a retinal ganglion cell line. *Graefes Arch Clin Exp Ophthalmol.* 2012;250:533–545.
25. Kovacević D, Mance TC, Markusić V. "Brilliant blue G" and "membrane blue dual" assisted vitrectomy for macular hole. *Coll Antropol.* 2011;35(Suppl 2):191–193.
26. Nagaradh K, Gokarn P. Choroidal neovascular membrane following vitreoretinal surgery for retinal detachment. *J Clin Ophthalmol*. 2019;4:212–215.

Downloaded from intl.iovs.org on 04/25/2024