

Titanium Powder 3D-Printing Technology for a Novel Keratoprosthesis in Alkali-Burned Rabbits

Otavio de Azevedo Magalhães¹, Rafael Jorge Alves de Alcantara¹,
José Alvaro Pereira Gomes¹, Jarbas Caiado de Castro Neto², and Paulo Schor¹

¹ Department of Ophthalmology and Visual Sciences, Paulista School of Medicine, Federal University of Sao Paulo, Sao Paulo, Brazil

² Institute of Physics, University of São Paulo, São Carlos, Brazil

Correspondence: Otavio de Azevedo Magalhães, 333 Mostardeiro St, office 503. Porto Alegre, RS 90430-001, Brazil. e-mail: otaviomaga@yahoo.com.br

Received: May 6, 2022

Accepted: July 19, 2022

Published: August 17, 2022

Keywords: keratoprosthesis; artificial cornea; 3D printing; KoBra; titanium powder

Citation: Magalhães ODA, de Alcantara RJA, Gomes JAP, Caiado de Castro Neto J, Schor P. Titanium powder 3D-printing technology for a novel keratoprosthesis in alkali-burned rabbits. *Transl Vis Sci Technol.* 2022;11(8):14. <https://doi.org/10.1167/tvst.11.8.14>

Purpose: To evaluate the surgical technique, clinical performance, and biocompatibility of a novel keratoprosthesis (KPro) named KPro of Brazil (KoBra) in an alkali-burned rabbit model.

Methods: Two-piece three-dimensional-printed titanium powder and polymethyl methacrylate KPros were implanted into 14 alkali-burned corneas of 14 rabbits using an autologous full-thickness corneal graft as the KPro carrier. Rabbits were examined weekly for 12 months to evaluate retention and postoperative complications. Anterior segment optical coherence tomography (AS-OCT) and scanning electron microscopy (SEM) were performed at the end of the experiment to evaluate the relationship between the KoBra and the carrier graft.

Results: All surgeries were performed without intraoperative complications, and the immediate postoperative period was uneventful. In 12 eyes (85.7%), the implanted KPros integrated into the operated eyes and maintained clear optics without extrusion or further complications over 12 months. Two eyes presented late postoperative complications that progressed to KPro extrusion: one had a presumed infectious keratitis, and the other had sterile stromal necrosis. AS-OCT demonstrated the correct relationship of the device and carrier graft in all remaining animals at the final follow-up. SEM findings indicate the integration of the porous structure of the back plate into the surrounding tissue.

Conclusions: Clinical evaluations, AS-OCT, and SEM findings indicate good biointegration of the implanted device into the corneal carrier graft. KoBra has the advantage of using recipients' own corneas as the prosthesis supporter, and its surgical procedure is relatively simple and safe.

Translational Relevance: Titanium three-dimensional-printed technology used in an animal limbal stem-cell deficiency model holds great promise for the treatment of corneal blindness in humans.

Introduction

The idea of replacing opaque corneal tissue with an optical artificial material came more than two centuries before the idea of transplantation.^{1,2} Keratoprosthesis (KPro) is indicated in cases of corneal blindness for which conventional treatment with penetrating keratoplasty (PK) has either failed or has a poor prognosis.³⁻⁵ A consistent meta-analysis showed that over the intermediate-term postoperative follow-up

period, patients receiving KPro are more likely to achieve improvement in their visual acuity and to retain this improvement than patients undergoing a repeated PK.⁶ Much effort has been focused on improving the biocompatibility and clinical performance of KPro.^{7,8} Integration of the device with the surrounding cornea is essential to prevent microorganism invasion and has an impact on its safety and efficacy. Polymethyl methacrylate (PMMA) is the most widely material used for the central optical portion of KPro because it is biologically inert, transparent, easy to fabricate,

and accommodating of a broad range of optical powers.

Titanium and its alloys can be processed via laser welding using sprayed powder manufacturing in three-dimensional (3D) printing. This method has advantages that include design flexibility, reduced processing costs, reduced waste, and the opportunity to more easily manufacture complex or custom-shaped implants.⁹ Using this technology, the characteristics of the product surface can be controlled to create ideal maximum porosity and roughness, which may increase tissue integration and prevent implantation failure. This process occurs by providing spaces for cells, vascular tissue, and even bone tissue ingrowth to form mechanical interlocking.^{10,11}

The most widely used device globally is the Boston type I KPro, and the newest model is made of a PMMA optical slab that is fixed to a titanium back plate mounted in a healthy allograft corneal graft as its carrier and support.⁴ This prosthesis has proven to be effective in surgical interventions to rehabilitate eyes with severe ocular surface disease, and more than 14,000 devices have been implanted.⁵ Unfortunately, because of costs and regulation issues, only 1200 KPro implantations are performed per year worldwide.⁷ Moreover, not all countries have a sufficient corneal donor tissue supply or eye bank organizations, particularly in the developing world, which limits the application of this KPro.⁸ Therefore, this study presents a novel, low-cost, titanium 3D printing device called the KPro of Brazil (KoBra), which uses recipients' own corneas as a prosthesis supporter. The goal of this study was to evaluate the retention rate, incidence of postoperative complications, and their management in alkali-burned rabbits.

Methods

This prospective, interventional, noncomparative, and nonrandomized study adhered to the ARVO Statement for the Use of Animals in Ophthalmology and Vision Research, as well as the tenets of the Declaration of Helsinki regarding the ethical treatment of animal subjects. The study protocol was approved by the Federal University of Sao Paulo Animal Care and Use Committee (protocol #936623-0719).

The KPro

The KoBra consists of a two-piece optical central stem made of PMMA, which has an attached mushroom-shaped anterior flange and a posterior plate

fabricated with 3D printed titanium (Plenum Inc, Jundiai, Brazil). The back plate secures the KPro to a recipient's own cornea as a prosthesis supporter. Direct laser metal sintering 3D printing and titanium powders (Ti-6Al-4V - Extra Low Interstitial) with spherical morphology and controlled particle size were used in this study with speed-curing processing parameters to prepare were used to prepare the back plates.

The anterior part of the optic (front plate) is 5.5 mm in diameter, and the internal part of the cylinder is 3.25 mm in diameter and 2.75 mm in length. The back plate skirt has 3 holes with outer diameters of approximately 7.5 mm and inner diameters of 3.3 mm, as well as a slit for locking to the optical stem (Fig. 1A).

Experimental Model of Corneal Alkali Burns

Fifteen New Zealand white rabbits aged 6 months and older weighing 3.0 to 4.0 kg were purchased (RG Farm, Suzano, Brazil) and housed at Federal University of Sao Paulo animal facilities. Throughout the study, rabbits were provided ad libitum access to diet and drinking water and housed individually in an automatically controlled environment (19–24°C with a relative humidity of 50%).

Alkali burn (NaOH, 1 M) was performed in the right eye of each rabbit under sedation (intramuscular ketamine/xylazine) and topical anesthetic for a total of 30 seconds after diamond burr superficial keratectomy. The injured eye was then thoroughly flushed with saline and managed with topical antibiotics for 6 weeks. One rabbit was excluded because of corneal perforation at the first month. The remaining 14 corneas developed different degrees of ulceration in the first week (Fig. 1B). The diffuse leucoma and vascularization presented by the injured eyes were evaluated for 8 weeks, which is the usual time interval between the creation of the limbal stem-cell deficiency (LSCD) model and its use in preclinical studies.^{11,12}

Surgical Technique and KPro Assembly

The anesthesia technique used for surgery on rabbits was developed with the assistance of a small animal veterinarian who used intramuscular dexmedetomidine hydrochloride at a dose of 0.02 mg/kg, ketamine hydrochloride at a dose of 15 mg/kg, 4 mg/kg of tramadol, and 0.4 mg/kg of meloxicam to induce anesthesia. During surgery, anesthesia and oxygen were delivered with a tight-fitting face mask placed over the mouth and nose under gaseous volatile isoflurane. The surgical procedure began with a double trephining of the host cornea at 4 mm centrally and 9.5 mm externally and set aside. The rabbit crystalline lens was

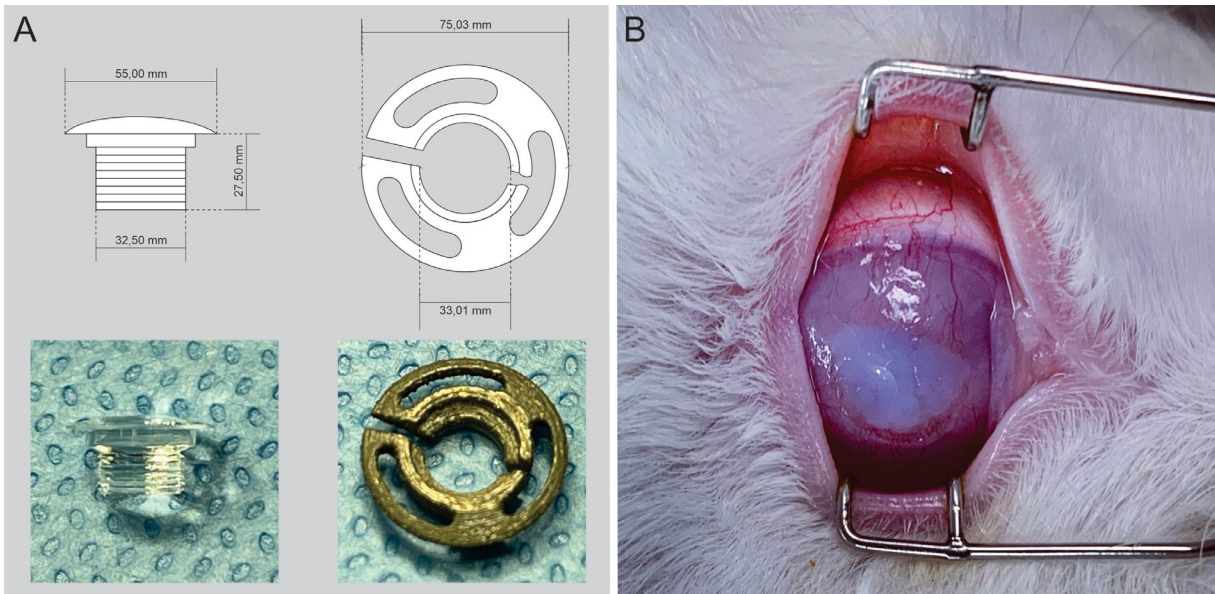


Figure 1. (A) Keratoprosthesis of Brazil (KoBra) design and dimensions. Mushroom-shaped front stem (optical component; *left*) made of PMMA; 7.5-mm diameter titanium back plate (*right*) with three holes and slit for locking of back plate to the optical component. (B) Alkali burn in rabbit ocular surface after epithelial debridement.

removed completely through an open sky extracapsular extraction, and an anterior chamber was formed with viscoelastics.

A PMMA cylinder was placed through the central opening and locked on within the titanium back plate extending behind the host cornea by using thumb pressure. The device was then inspected for proper assembly under a surgical microscope. The host graft was then sutured back in place as in a traditional PK with 16 interrupted 10-0 nylon sutures and the knots rotated posteriorly (Fig. 2A). This step was followed by subconjunctival injections of gentamicin and dexamethasone. All surgeries were performed by a single surgeon (O.A.M.) in a similar manner. After the implantation, the animals were treated with eye drops containing topical antibiotics (tobramycin 0.3%) and steroids (dexamethasone 0.1%) every 12 hours for the first 2 weeks and once daily for 4 weeks. At the end of the study, the rabbits were euthanized and enucleated.

Evaluation of KPro Biointegration

Animals were monitored routinely throughout the 12-month observation period for systemic clinical signs and body weight changes. The implanted eyes were examined on a weekly basis for evidence of complications, such as melting, aqueous leakage, retroprosthetic membrane (RPM) formation, endophthalmitis, infectious keratitis, retinal detachment, and proliferative vitreoretinopathy. The examinations were done using

portable slit-lamp microscopy and binocular indirect ophthalmoscopy with a 20-diopter lens. Intraocular pressure (IOP) was tested by finger palpation. Procedures that would promote retention of the prosthesis, such as conjunctival flap and tarsorrhaphy were performed if necessary. In case of extrusion, the maximal retention periods of the KPro were recorded, and the animal was euthanized.

Anterior Segment Optical Coherence Tomography (AS-OCT)

Time-domain AS-OCT (Visante, Carl Zeiss Meditec, Dublin, CA) was used to obtain high-resolution images of the KPro in vivo. The KPro was visible as a T-shaped cylinder with corrugated sides through the center of the cornea. The front plate, optical cylinder, back plate, carrier corneal graft, and RPM were visualized distinctly as described in the literature.^{13,14}

Scanning Electron Microscopy (SEM) Evaluation

The KoBra-implanted eyes were enucleated at the end of follow-up and fixed in 2.5% glutaraldehyde solution at 4°C overnight. After washing two times with phosphate-buffered saline, the fixed cells were dehydrated with an ascending sequence of ethanol

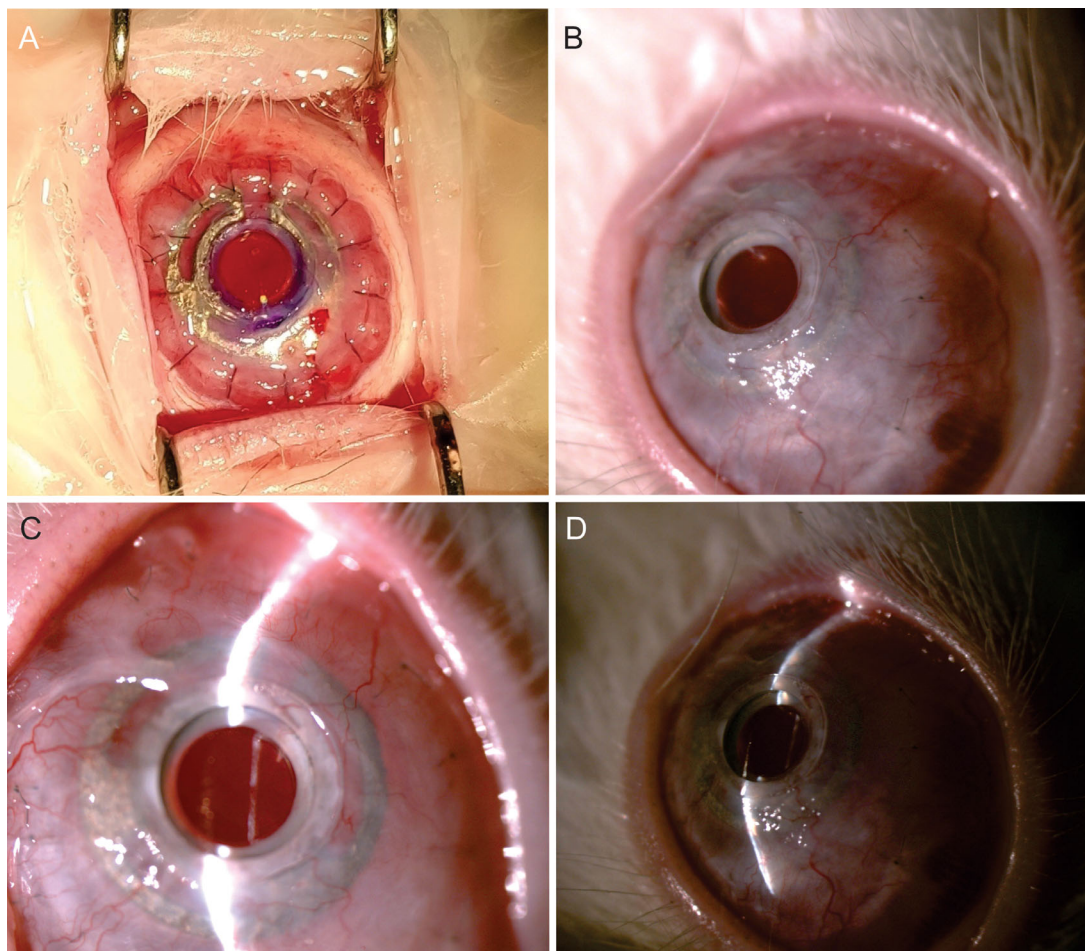


Figure 2. Postoperative Keratoprosthesis of Brazil (KoBra) implantation at three distinct time points. (A) Immediate KoBra implantation. (B, C) Well-placed KoBra after 6 months of follow-up. (D) Well-placed KoBra in a heavily vascularized cornea after 12 months of follow-up with mild RPM formation.

concentrations. Subsequently, the samples were left at room temperature for 24 hours and coated with a 5 nm of gold/ palladium.¹⁵ The microstructure surface topography of a Ti-6Al-4V sample was examined using Field Emission SEM microscopy (model Quanta FEG 450) operated at 30 kV. All common biocompatibility parameters and the amount of cellular infiltration into the device's back plate were evaluated.

Results

All 14 rabbits survived the operation without intra-operative complications (Table). No operated eyes had significant surgical complications regarding the positioning or fixation of the KoBra. The animals seemed comfortable with no signs of pain or excessive discharge, despite minimal conjunctival inflammation in the first month postoperatively. Limited secto-

rial corneal thinning was noted in three operated eyes at the graft–host junction site (3 months postoperative in two animals and 5 months in one animal), and a full conjunctival flap in two and lateral tarsorrhaphy in one animal was performed in the subsequent sessions. No further thinning, leakage, or extrusion was observed in these animals.

One rabbit's KoBra extruded 4 months after the operation because of a presumed infectious keratitis of an exposed suture. At 9 months, another KPro extruded owing to IOP elevation and aggressive corneal melting. Owing to a lack of recovery, the animals were sacrificed in a humane manner. A mild RPM formation was found in five rabbit eyes at the end of follow-up (41.6%), which was not sufficient to block indirect fundoscopic examination. Elevated IOP was found in four rabbit eyes throughout the study (28.6%), including the one that had extrusion. At the end of the experiment (12 months after operation), slit-lamp examination revealed that the KoBra was found in situ in

Table. Animal Details and Outcomes of KoBra Implantation

Rabbit No.	Gender	Follow-Up (Months)	RPM	Elevated IOP	Postoperative Interventions	Postoperative Complications
1	Female	12	+	–	–	–
2	Male	9	–	+	–	Corneal melting and glaucoma - extrusion
3	Male	12	+	+	–	–
4	Female	12	+	–	Full conjunctival flap	–
5	Male	12	–	–	–	–
6	Female	12	+	–	–	–
7	Female	12	–	+	–	–
8	Female	4	–	–	–	Presumed infectious keratitis extrusion
9	Male	12	–	–	–	–
10	Male	12	+	–	Lateral tarsorrhaphy	–
11	Female	12	–	–	–	–
12	Male	12	+	+	–	–
13	Male	12	–	–	Full conjunctival flap	–
14	Female	12	+	–	–	–

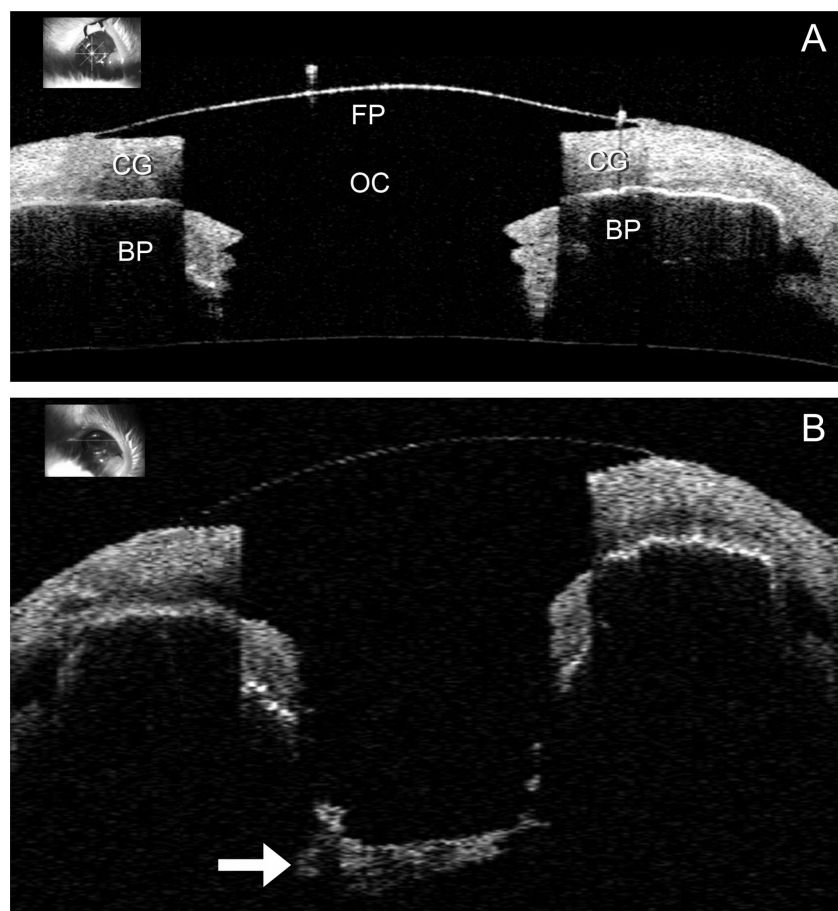


Figure 3. In vivo AS-OCT of the KoBra after 12 months of follow-up. (A) The front plate (FP) and optical cylinder (OC) are clearly visible over the corneal graft (CG). The titanium back plate (BP) appears dark in OCT under CG. (B) RPM is clearly visible posterior to the optical cylinder (arrow).




Figure 4. SEM images of the 3D-printed implant. (A) Rough surface characteristic of the additive layer manufactured material. (B) Collagen fibrils arranged in parallel in the collagen matrix, as well as fibril bundle. (C) Higher magnification of selection in inset. (D) Diffuse infiltration of collagen fibril deposition within the back plate's microporosities.

12 eyes without keratolysis, extrusion, infection, or hemorrhage, resulting in a retention rate of 85.7% (Figs. 2B–D). Indirect ophthalmoscopy revealed transparent vitreous humor in all animals, allowing clear views of the physiologic retina and optic nerve. In addition, no RPM formation was observed in seven rabbits post mortem after enucleation. No unusual or concerning systemic clinical signs were found during the observation period.

AS-OCT and SEM Findings

AS-OCT visualized the correct relationship of the KoBra and carrier graft in all animals at the final follow-up. In addition, it demonstrated the relationship of the epithelium to the anterior surface of the KPro front plate (Fig. 3A). The most common

finding was RPM formation, which we found in 41.6% of KoBra-implanted eyes (Fig. 3B). No spaces or gaps were identified between the corneal carrier graft and the KPro. SEM imaging clearly showed a rough surface characteristic of the additive layer manufactured material (Fig. 4A). The explanted devices showed diffuse collagen fibrils arranged in parallel throughout the surface, as well as fibril bundles (Fig. 4B). Diffuse infiltration of collagen fibril deposition in the micropores of the device was observed, suggesting improved biointegration (Figs. 4C and 4D).

Discussion

Titanium and its alloys have a proven track record as biomedical implants owing to their excel-

lent biocompatibility.¹⁶ There are key advantages in titanium alloy fabrication via advanced powder manufacturing routes such as additive layer manufacturing and 3D printing, which include design flexibility, lower processing costs, reduced waste, energy efficiency, and improved functionality, as demonstrated in several studies. Compared with conventional machining methods such as turning and milling, titanium powder 3D printer saves up 40% in production costs, depending on production output levels. The implants produced by direct metal laser sintering 3D printing have an intrinsically rough surface, which is beneficial for biointegration. The implants made by this technology have a porous structure and, when compared with controls with standard surfaces that have been machined, sandblasted, and etched, direct metal laser sintering technology showed the highest increase in bone-to-implant contact in dental implants.¹⁷ In addition, materials with high surface roughness have been demonstrated to induce better tissue attachment *in vivo* and *ex vivo*, demonstrating stronger cellular attachment.¹⁸

KPro studies have included a range of underlying pathologic characteristics, and most have not reported separately on patients with chemical burn. It has been reported that persistent corneal epithelial defect formation is significantly more common in eyes with LSCD owing to chemical injury.¹² Several postoperative complications are more common in eyes with LSCD, including persistent corneal epithelial defect formation, sterile stromal necrosis, and infectious keratitis, but the KoBra presented a good retention rate of 85.7% over a period of 12 months.

We believe that our retention rate is consistent with publications from other groups that reported outcomes in LSCD.^{19,20} The rate of RPM formation was reported as 61%, and the rate of glaucoma onset or progression was 26% for B-KPro in the onset of LSCD, which are similar to our results.^{19,20} AS-OCT captured the presence of an intact epithelial layer covering the junction between the carrier donor corneal tissue and the edge of the KPro front plate. This configuration would presumably decrease the infection risk by acting a barrier for the entry of microorganisms between the front plate and the carrier graft. SEM showed diffuse infiltration and deposition of collagen fibrils within the back plate's microporosities without significant inflammation.

Another recent device named CorNeat KPro was also tested in rabbits before human implantation. Although the follow-up time and the number of rabbits were lower than ours (eight animals), the retention rate was 87.5% at the end of the 6-month follow-up period.²¹ The study also indicated good integration

of the implanted device into the surrounding tissue, yet the implantation procedure had a greater learning curve and presented more surgery-related complications compared with the KoBra.

The limitations of this study include the relatively small number of animals and short-term follow-up for the KPro.²² The difficulty of IOP measurement was also another limitation characteristic of KPros. Perhaps an antiglaucomatous drop (or more than one topical drug) would have prevented IOP elevation in our animal model. Some authors encourage KPro implantation concomitantly with a glaucoma drainage device to improve clinical outcomes.²³ KoBra's indication restriction is that it still requires a normal tear film (wet surface) and blinking for implantation. This limitation is exactly the same as the most common and successfully implanted artificial cornea thus far, the B-KPro type I.

Although complications occurred and seemed to strike at any time after implantation, the available data are encouraging. The learning curve for KoBra implantation is the same as that of PK with the addition of only the KPro assembly to the traditional procedure. It is also important to mention that the KoBra does not require a donor graft. For the underlying economics in the developing world and shortage of grafts, this feature is important. Also, a more affordable and adjustable device to fit various thicknesses of corneal lesions would stimulate the implantation of these artificial devices. It is a relatively safe, effective, and cost-saving procedure that is suitable for use in the developing world.

Conclusions

We tested a novel titanium 3D-printing KPro design and PMMA in an animal LSCD *in vivo* setting. The clinical and ultrastructural analysis demonstrated a good outcome of the use of this new technology. These encouraging results open the possibility for clinical studies with KoBra in humans.

Acknowledgments

The authors thank Daniela Nogueira Cremonini for her surgical assistance during experiments and Fabricio Rassy for his anesthesia assistance and preoperative care of the rabbits.

Supported by a grant of the Brazilian National Council for Scientific and Technological Development (protocol number 0023936254028624). The funding

organization had no role in the design or conduct of this research.

The Federal University of Sao Paulo (inventor: Otavio A Magalhaes) and Plenum Inc. have issued Brazilian design patent for the 3D printing titanium back plate in the study.

Disclosure: **O.D.A. Magalhães**, (P); **R.J.A. de Alcantara**, None; **J.A.P. Gomes**, None; **J. Caiado de Castro Neto**, None; **P. Schor**, None

References

- Chirila TV, Hicks CR. The origins of the artificial cornea: Pellier de Quengsy and his contribution to the modern concept of keratoprosthesis. *Gesnerus*. 1999;56:96–106.
- Franceschetti A. Corneal grafting. *Trans Ophthalmol Soc UK*. 1949;69:17–35.
- Oliveira L, Cade F, Dohlman C. Keratoprosthesis in the fight against corneal blindness in developing countries. *Arq Bras Oftalmol*. 2011;74:5–6.
- Colby KA, Koo EB. Expanding indications for the Boston keratoprosthesis. *Curr Opin Ophthalmol*. 2011;22:267–273.
- Aravena C, Yu F, Aldave AJ. Long-term visual outcomes, complications, and retention of the Boston type I keratoprosthesis. *Cornea*. 2018;37:3–10.
- Ahmad S, Mathews PM, Lindsley K, et al. Boston type I keratoprosthesis versus repeat donor keratoplasty for corneal graft failure: a systematic review and meta-analysis. *Ophthalmology* 2016;123:165–177.
- Gonzalez-Andrades M, Sharifi R, Islam MM, et al. Improving the practicality and safety of artificial corneas: pre-assembly and gamma-rays sterilization of the Boston keratoprosthesis. *Ocul Surf*. 2018;16:322–330.
- Yaghouti F, Dohlman CH. Innovations in keratoprosthesis: proved and unproved. *Review Int Ophthalmol Clin*. 1999;39:27–36.
- Shah FA, Omar O, Suska F, et al. Long-term osseointegration of 3D printed CoCr constructs with an interconnected open-pore architecture prepared by electron beam melting. *Acta Biomater*. 2016;36:296–309.
- Murr LE, Gaytan SM, Martinez E, Medina F, Wicker RB. Next generation orthopaedic implants by additive manufacturing using electron beam melting. *Int J Biomater*. 2012;2012:245727.10.
- Selver OB, Durak I, Gu'rdal M, et al. Corneal recovery in a rabbit limbal stem cell deficiency model by autologous grafts of tertiary outgrowths from cultivated limbal biopsy explants. *Mol Vis*. 2016;22:138–149.
- Sejpal K, Yu F, Aldave AJ. The Boston keratoprosthesis in the management of corneal limbal stem cell deficiency. *Cornea*. 2011;30: 1187–1194.
- Shapiro BL, Cortes DE, Chin EK, et al. High-resolution spectral domain anterior segment optical coherence tomography in type I Boston keratoprosthesis. *Cornea*. 2013;32:951–955.
- Fernandez AG, Radcliffe NM, Sippel KC, et al. Boston type I keratoprosthesis-donor cornea interface evaluated by high-definition spectral-domain anterior segment optical coherence tomography. *Clin Ophthalmol*. 2012;6:1355–1359.
- Salvador-Culla B, Jeong KJ, Kolovou PE, et al. Titanium coating of the Boston keratoprosthesis. *Transl Vis Sci Technol*. 2016;5(2):17.
- Zhou C, Lei F, Chodosh J, et al. The role of titanium surface microtopography on adhesion, proliferation, transformation, and matrix deposition of corneal cells. *Invest Ophthalmol Vis Sci*. 2016;57:1927–2019.
- Stübinger S, Mosch I, Robotti P, et al. Histological and biomechanical analysis of porous additive manufactured implants made by direct metal laser sintering: a pilot study in sheep. *J Biomed Mater Res Part B Appl Biomater*. 2013;101:1154–1163.
- Hacking SA, Boyraz P, Powers BM, et al. Surface roughness enhances the osseointegration of titanium headposts in non-human primates. *J Neurosci Methods*. 2012;211:237–244.
- Aravena C, Bozkurt TK, Yu F, Aldave AJ. Long-term outcomes of the Boston type I keratoprosthesis in the management of corneal limbal stem cell deficiency. *Cornea*. 2016 Sep;35(9):1156–1164.79.
- Lee WB, Shtein RM, Kaufman SC, et al. Boston Keratoprosthesis: outcomes and complications. A report by the American Academy of Ophthalmology. *Ophthalmology* 2015;122:1504–1511.
- Litvin G, Klein I, Litvin Y, et al. CorNeat KPro: ocular implantation study in rabbits. *Cornea*. 2021;40:1165–1174.
- Belin MW, Guell JL, Grabner G. Suggested guidelines for reporting keratoprosthesis results: consensus opinion of the Cornea Society, Asia Cornea Society, EuCornea, PanCornea, and the KPro Study Group. *Cornea*. 2016;35:143–144.
- Lenis TL, Chiu SY, Law SK, Yu F, Aldave AJ. Safety of concurrent Boston type I keratoprosthesis and glaucoma drainage device implantation. *Ophthalmology*. 2017;124:12–19.